

# Dual Infection in a COVID 19 Patient – Mucormycosis and Actinomycosis

Minnu Roy<sup>1\*</sup>, Sankar S<sup>2</sup>, Rajiv Kumar<sup>3</sup>

<sup>1</sup>Junior Resident, Department of Pathology, Government Medical College Kottayam, Kerala, India

<sup>2</sup>Professor & Head, Department of Pathology, Government Medical College Kottayam, Kerala, India

<sup>3</sup>Assistant Professor, Department of ENT, Government Medical College Kottayam, Kerala, India

DOI: [10.36348/sjpm.2021.v06i01.010](https://doi.org/10.36348/sjpm.2021.v06i01.010)

| Received: 10.01.2021 | Accepted: 21.01.2021 | Published: 30.01.2021

\*Corresponding author: Dr. Minnu Roy

## Abstract

Since the rise of the pandemic COVID 19, we see a variety of clinical manifestations of Corona virus multisystem wise. During and post infection, patients are prone for cardiac diseases and its complications, even sudden deaths following thromboembolism. Fungal infections are also now making their way into this pandemic as secondary infections due to altered immunity in these individuals. We present a patient of COVID 19 infection who developed dual infection– mucormycosis and actinomycosis. We also report about mucor mycosis in a non COVID patient who was immunocompromised due to diabetes mellitus.

**Keywords:** Mucormycosis, actinomycosis, Covid 19.

**Copyright © 2021 The Author(s):** This is an open-access article distributed under the terms of the Creative Commons Attribution **4.0 International License (CC BY-NC 4.0)** which permits unrestricted use, distribution, and reproduction in any medium for non-commercial use provided the original author and source are credited.

## INTRODUCTION

Mucormycotina / zygomycetes are seen in the nature widely distributed and they are of no harm to immunocompetent individuals. But when they affect immunosuppressed individuals, they take its invasive form resulting in vascular invasion, thrombosis and necrosis.

Actinomycosis is a rare anaerobic bacterial infection which can lead on to suppurative lesion, abscess formation and sinuses. Herein, our patient had both mucor mycosis and actinomycosis involving the paranasal sinuses.

## CASE REPORT

A 47 year old male patient who is a known case of type 2 diabetes mellitus and systemic hypertension (on treatment) presented with complaints of headache for 3 weeks, bilateral nasal obstruction, swelling over forehead. He then had foul smelling nasal discharge. Later he developed blackish discoloration of hard palate and oral ulcerations, pain over mouth, bilateral facial swelling and blackish discoloration of face and blurring of vision.

On examination, there was broadening of nose, blackish discoloration of mucosa over the hard palate with erosions, bilateral periorbital edema, restricted ocular movements.

On MRI examination of brain, an aggressive infection with the possibility of fungal infection in cheeks, nose, maxillary, ethmoid, sphenoid sinuses with involvement of bilateral pterygoid plates, masticator space, parotid space soft tissues, paravertebral space and retropharyngeal spaces and associated osteomyelitis was suggested. Intracranial extension was also noted.

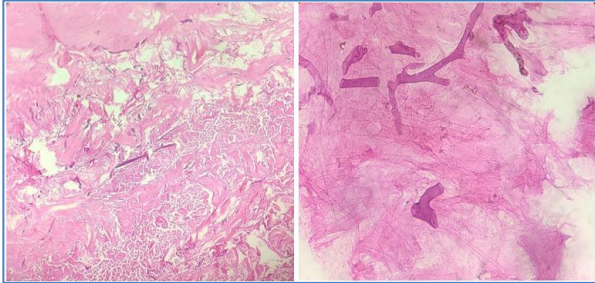
The patient was then tested and found out to be positive for Covid 19. The patient was on liposomal amphotericin B and symptomatic treatment was also given.

A biopsy was taken and sent from the blackish discoloration in the hard palate. On histopathological examination the patient was diagnosed with mucormycosis. Later he underwent debridement of the devitalized areas in the face and tracheostomy was also done.

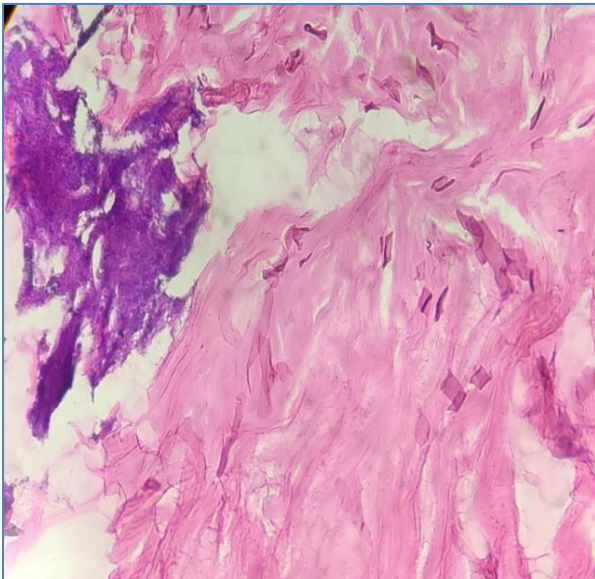


**Fig-1, 2: Specimen received for histopathological examination**

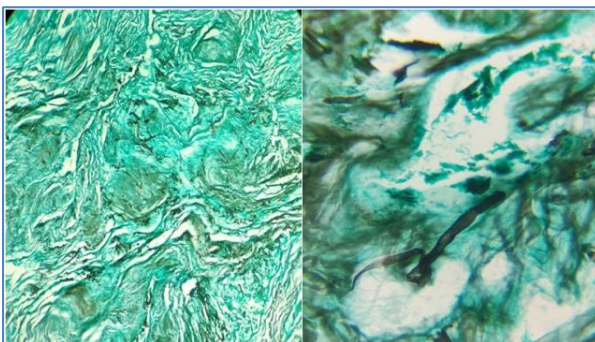
On microscopy, tissue showed extensive necrosis and fungal organisms with broad non septate hyphae branching at right angles. A few actinomycotic colonies were also seen.



**Fig-3, 4: Demonstration of fungal hyphae**



**Fig-5: Demonstration fungal hyphae and actinomycotic colonies in H& E stain**



**Fig-6, 7: Demonstration of fungal hyphae in GMS**

The second case is a 60 year old male who was a known diabetic. He presented with complaints of left sided facial pain, left eyelid swelling, nasal obstruction and blood stained nasal discharge. On examination, he had polypoidal and devitalized tissue filling the maxillary antrum with erosion of roof and posterior

wall of maxillary sinus. His MRI brain and base of skull showed erosions involving the maxillary sinus wall, inferior wall of orbit, greater wing of sphenoid (left) and pterygoid plates(left) with the possibility of a fungal infection.

## DISCUSSION

Mucormycosis (earlier known as zygomycosis) is an opportunistic fungal infection caused by fungi belonging to Mucormycetes (*Mucor*, *Rhizopus*, *Lichtheimia*, *Cunninghamella*) which are usually seen in the soil and water. They are transmitted by airborne asexual spores. They infect immunosuppressed individuals and the major predisposing factors are hematologic malignancies, stem cell and solid organ transplants, neutropenia, corticosteroid use, diabetes mellitus, iron overload and breakdown of cutaneous barrier [1, 3]. The three primary sites of invasion are nasal sinuses, lungs and gastrointestinal tract depending on the mode of infection (inhaled or ingested). Six clinical syndromes can occur namely Rhino orbito cerebral, pulmonary, cutaneous, gastrointestinal disseminated and uncommon presentations [3].

Rhinocerebralzygomycosis is mostly associated with acute diabetes. The fungus spreads from nasal sinuses to orbit and brain. Death occurs in a few days if the infection is not identified and treated at the earliest. Most of these infections are due to the species *Rhizopusoryzae*. The main sites of infection are the nasal turbinates and the paranasal sinuses. Spread from the primary site to other sites occurs by direct extension [2].

Pathogenesis: The organisms are first defended by the macrophages by phagocytosis and non-oxidative killing of the germinating sporangiospores. Mucormycotinahyphal components are recognized by the TLR 2 which results in a pro inflammatory cascade of cytokines (IL6, TNF $\alpha$ ). Neutrophils also play a major role in destroying hyphae after germination by directly damaging the hyphae walls. If these defense mechanisms are weaker, the chances to have an invasive infection are higher. The availability of free iron also increases the risk of infection [1].

Clinical features: When the nose, eyes and brain are involved, the symptoms develop faster. There can be black and blood tinged mucus, necrotic tissue in the nose, severe frontal headaches, chills and fever. When there is associated brain and meninges invasion orbital swelling occurs which can be ominous. In diabetics (with acidosis), the main features of rhinocerebral infection includes rapid development of sinusitis, inflammation of the orbital tissues, ophthalmoplegia, proptosis and signs of meningoencephalitis.

It is not a contiguous disease and do not spread from one person to the other [2]. Histopathology: This fungus usually induces a pyogenic inflammatory reaction which is characterised by abscess formation and suppurative necrosis. They cause local tissue necrosis, invade the arterial walls; penetrate the periorbital tissues and cranial vault. When the tissues are heavily infected, dense polymorphonuclear infiltrates are seen. The hyphae are characteristically broad, usually aseptate, thin walled, with non-parallel walls and range in width from 3 - 25µm and in length upto 200 µm. They are empty, having focal bulbous dilatations non dichotomous irregular branching mostly at right angles. Transected hyphae can mimic large empty yeast cells or empty spherules of *Coccidioides*. Sporangia are not usually seen in the tissue. In H&E stains, the hyphae are basophilic or amphophilic [2].

Actinomycetes are bacteria that cause chronic suppurative diseases characterized by extensive fibrosis, multiple abscesses and sinus tracts that drain the suppurative lesions. The principal agent of infection in man is *Actinomyces israelii*. They usually infect cervico - facial areas in humans followed by abdominal, genital and thoracic areas as discharging sinuses [4]. It commonly involves cervicofacial areas in humans. It can follow with or without any trauma. From the initial sites, the infection spreads to adjacent areas. There will be associated swelling of the infected tissues. Later abscess forms and sinus tracts appear. If untreated the infection can extend to sinuses, orbit and cranial bones.

Histopathology: There is formation of abscess that contains actinomycotic granules (organized aggregates of filaments) and are encapsulated by fibrosing granulation tissue. The granules usually appear as round, oval, scalloped masses that are solid and characteristically bordered by a radial corona of eosinophilic, club like Splendore-Hoeppli material. The entire granule is basophilic in H&E stain. The granules may range from 30 - 3000µm or more in maximum

diameter. Individual filaments are rarely seen. They are colored deep bluish purple and are well demonstrated with the tissue Grams stain. They are also demonstrated by GMS and Giemsa stains [2].

Secondary infections are seen in Covid infected patients due to altered immunity (reduced number of T lymphocytes, CD<sub>4</sub>, CD<sub>8</sub>) mostly in individuals with pre-existing immunosuppression. Only a few cases have been reported so far in the literature related to Covid 19 and mucor mycosis [5].

## CONCLUSION

In this scenario of Covid 19 pandemic a myriad of complicated clinical presentations are seen in the individuals affected. Dual infection of mucor mycosis and actinomycosis is a rare entity especially in this case. But we are not sure whether the patient got fungal infection and got aggravated due to covid or he got the fungal infection post covid infection. Immediate diagnosis and treatment is mandatory since this is an emergency and can lead on to fatal complications. The second case highlights the importance of fungal infection complicated by diabetes.

## REFERENCES

1. Pathologic Basis of Disease, Robbins and Cotran, 10th edition, 339-340.
2. A Color Atlas and Textbook of the Histopathology of Mycotic Diseases. 26-29, 122-127.
3. Alexandra, S. (2019). Francois Danion and Fanny Lanternier: J. Fungi, 5:23.
4. A rare case of sino nasal actinomycosis – enigmatic presentation. (2018). International Journal of Otorhinolaryngology and Head and Neck Surgery, 4(3); 863.
5. Mehta, S., Pandey, A. (September 30, 2020). Rhino – orbital Mucormycosis Associated with Covid 19. Cureus 12(9):e10726.