

Endometrioid Carcinoma Ovary – A Case Report

Dr. V. Rama Murthy M.D.^{1*}, Dr. Annie Nitisha. C.², Dr. Sai Sudha. M.³

¹Professor of Pathology, Department of Pathology, Sree Balaji Medical College and Hospital, 7, Works Road, Shankar Nagar, Chromepet, Chennai, Tamil Nadu 600044, India

²Postgraduate in Pathology, Department of Pathology, Sree Balaji Medical College and Hospital, 7, Works Road, Shankar Nagar, Chromepet, Chennai, Tamil Nadu 600044, India

³Assistant professor, Department of Pathology, Sree Balaji Medical College and Hospital, 7, Works Road, Shankar Nagar, Chromepet, Chennai, Tamil Nadu 600044, India

DOI:10.36348/SJPM.2019.v04i09.003

| Received: 27.08.2019 | Accepted: 04.09.2019 | Published: 11.09.2019

*Corresponding author: Dr. V. Rama Murthy

Abstract

Endometrioid carcinoma of ovary is a subtype of epithelial tumours of the ovary. It can be distinguished from serous and mucinous tumours by presence of tubular glands resembling that of malignant endometrium. We report a case of endometrioid carcinoma of ovary which occurred in a 60years old women. The patient presented with abdominal distention and she underwent a hysterectomy with left side salphingo- ooherectomy. Histologically, ovarian tumour was composed of tubular glands with squamous metaplasia and Sertoli cell tumour like pattern in some foci and was diagnosed as Endometrioid carcinoma- ovary.

Keywords: Endometrioid carcinoma, Malignant tubular glands, Squamous metaplasia, Sertoli cell pattern.

Copyright @ 2019: This is an open-access article distributed under the terms of the Creative Commons Attribution license which permits unrestricted use, distribution, and reproduction in any medium for non-commercial use (NonCommercial, or CC-BY-NC) provided the original author and sources are credited.

INTRODUCTION

Endometrioid ovarian tumours are classified under epithelial tumours of ovary and it accounts for about 10% of all primary ovarian cancers. It is a neoplasm closely resembling endometrial endometrioid adenocarcinomas. Endometrioid tumours are subclassified as benign, borderline and malignant neoplasms. Women with endometrioid ovarian cancer presents at the younger age and with earlier stage disease when compared with other ovarian cancers. Co-existent endometriosis can often be demonstrated and some of the tumours can be seen arising from those endometriotic foci.

CASE REPORT

A 60 years old women was admitted to the hospital with the complaints of abdominal distension. On physical examination fullness in the Left iliac fossa, left lumbar, suprapubic and umbilical region was noted. Pelvic ultrasound disclosed large cystic ovarian neoplasm occupying whole of the abdomen. CT abdomen also reveals large abdomino- pelvic, cystic space occupying lesion of the left side probably arising from left ovary? Serous cystadenocarcinoma. She

underwent total abdominal hysterectomy with left side salphingo-oophorectomy.

On gross examination, there was a globular ovarian cyst with bosselated surface and thick cyst wall. The cyst wall was multiloculated with solid and cystic areas. On cross section yellowish-white solid areas with haemorrhagic fluid filled cysts are seen. Tissue samples were fixed in 10% buffered neutral formalin and embedded in paraffin. Sections were stained with hematoxylin and eosin.

Histologically, lesion was composed of oval to polygonal cells with enlarged pleomorphic nuclei and prominent nucleoli. Mitotic figures are also seen. Tumour cells are arranged back to back in glandular, micro-glandular and cribriform pattern. Sertoli cell tumour like pattern is seen in some foci, with glands infiltrating surrounding stroma. Focal hyalinization, squamous metaplasia and myxoid degeneration with few areas of calcification are also seen. The tumour is reported as Moderately differentiated endometrioid carcinoma ovary, Grade – II.

GROSS APPEARANCE

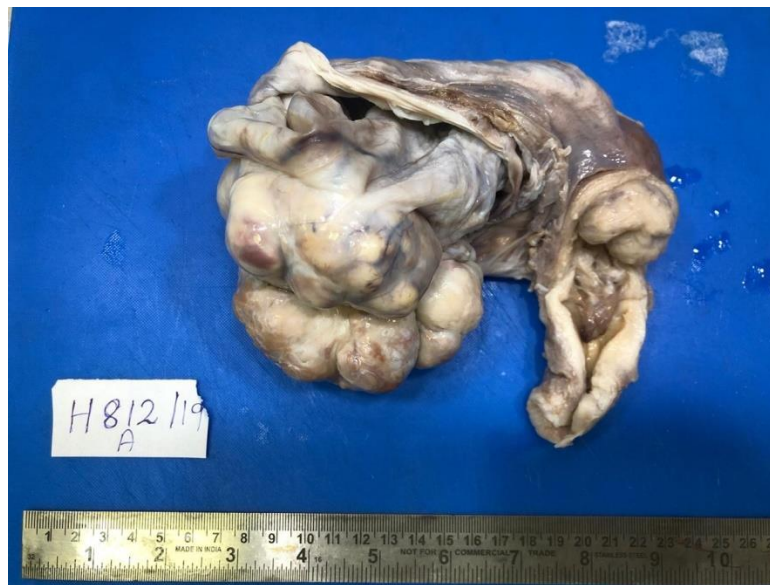

Fig-1: Globular ovarian cyst with bosselated external surface and thick cystic wall. The ovarian cyst is multi located with solid and cystic areas

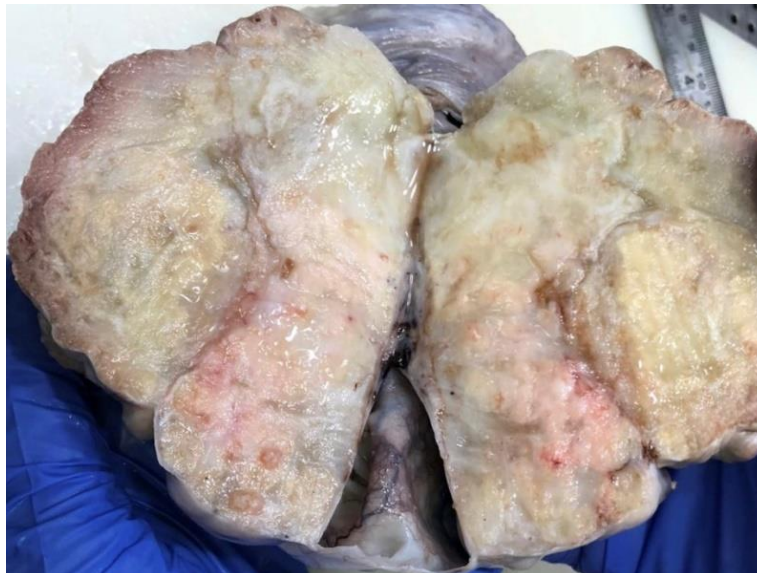

Fig-2: Cut section reveals yellowish white firm solid and Cystic areas

MICROSCOPIC APPEARANCE

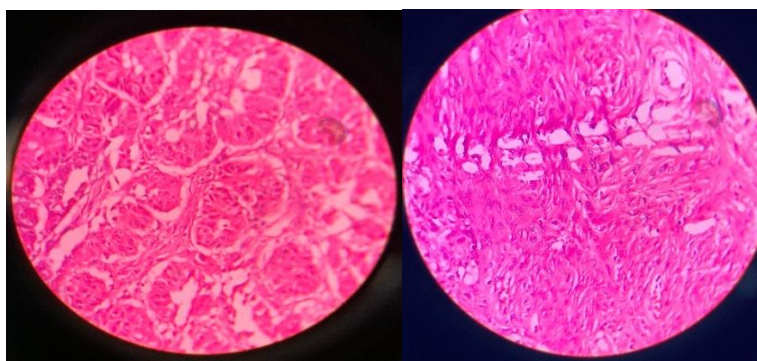


Fig 3 & 4: Tumor cells arranged in tubular glands and a foci of Squamous metaplasia

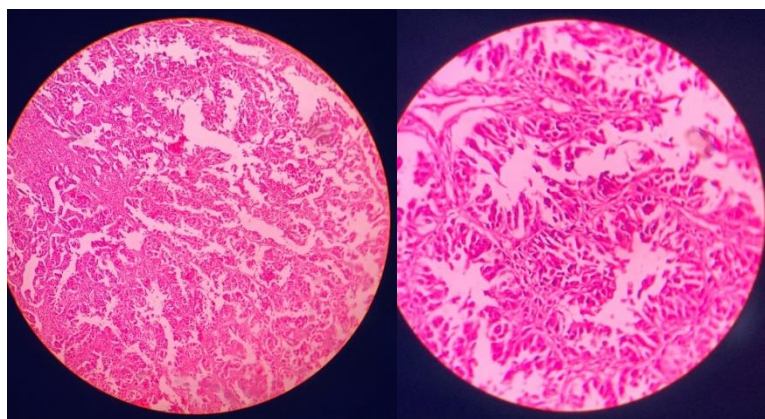


Fig 4 & 5: Shows Sertoli cell tumour – like area

DISCUSSION

Endometrioid carcinoma affects 5th and 6th decade of life. About 42% of tumours associate with endometriosis of same ovary and 15-20% co-exist with endometrial carcinoma [5], when it is associated it affects 10 years younger women on an average [2, 5]. Hyper estrogenic states have a role in the transformation of endometriosis [4]. Many are asymptomatic and present as pelvic mass to hospital. Pain may or may not be the complaint, but they generally present in early disease like in stage I and about 17% of the cases presents with bilateral involvement of ovaries with elevated CA125 [2]. Endometrioid carcinoma has survival rate of 5-10 years [3]. Our patient presented to hospital with abdominal distention. Gross appearance of tumour is similar as other epithelial lesions with solid and cystic components [1, 5]. Histologically, the glands look tubular similar to endometrium with squamous differentiation in 30-50% and luteinized stromal cells seen in 12% cases.

Endometrioid carcinoma have different variants like Spindle cell variant, ciliated cell variant, clear cell variant, oxyphilic variant which has large polygonal cell with abundant eosinophilic cytoplasm with central nuclei and prominent nucleoli [2]. In sex cord stromal type pattern we see tubular or small rosette like glands mimicking an adult granulosa cell tumour [2]. Another most important one is Sertoli form variant which shows areas of Sertoli and Sertoli-leydig cell resemblance [2].

To rule out metastasis with primary tumour, IHC is essential by using vimentin, epithelial membrane antigen (EMA) and cytokeratin (CK) [2]. The ovarian tumour shows positivity for EMA and CK, negativity for vimentin. Whereas for endometrial and cervical tumours vimentin and EMA are positive, CK is

negative but in squamous differentiation-endometrium alone CK is also positive.

CONCLUSION

Endometriotic cyst ovary is usually associated with endometrioid carcinoma ovary. In this case there is no evidence of endometriosis and Endometrium of uterus show normal histology.

This case is presented because of its rare variety and its associated histo-morphological features like Sertoli cell tumour like pattern and squamous metaplasia.

REFERENCES

1. Long, M. E., & Taylor, H. C. (1964). Endometrioid carcinoma of the ovary. *American Journal of Obstetrics & Gynecology*, 90(7), 936-950.
2. Kurman, R. J., Carcangiu, M. L., Herrington, C. S., & Young, R. H. (2014). International Agency for Research on Cancer Lyon, WHO Classification of Tumours of Female Reproductive Organs.
3. Czernobilsky, B., Silverman, B. B., & Mikuta, J. J. (1970). Endometrioid carcinoma of the ovary. A clinicopathologic study of 75 cases. *Cancer*, 26(5), 1141-1152.
4. Tsuzuki, Y., Kikuchi, I., Nojima, M., Yoshida, K., Hashizume, A., & Tomita, S. (2017). A case report: ovarian Sertoli-Leydig cell tumor with hyperestrogenism and endometrial hyperplasia in a postmenopausal woman. *Japanese clinical medicine*, 8, 1179066017695239.
5. Kumar, V., Abbas, A. K., & Fausto, N. (2017). *Robbins and Cotran pathologic basis of disease, professional edition e-book*. Elsevier health sciences. W B Saunders Co.