

CBCT- A Boon for Implant Dentistry

Dr. Abbasi Begum Meer Rownaq Ali^{1*}, Dr. Khuthija Khanam², Dr. Keerthi G. K³, Dr. Asok Mathew⁴, Dr. Afsar Sharief S. N. H⁵

¹M.D.S Prosthodontist, Lecturer at Dar Al Uloom University, Riyadh, Saudi Arabia

²M.D.S Prosthodontist, Lecturer at Dar Al Uloom University, Riyadh, Saudi Arabia

³M.D.S Prosthodontist, Ajman University, University Street, Al jerf 1 - Ajman - United Arab Emirates

⁴M.D.S Oral Medicine and Radiology, Assistant Professor, Department of Surgical Sciences, Ajman University, University Street, Al jerf 1 - Ajman - United Arab Emirates

⁵M.D.S Prosthodontist, Consultant Prosthodontist & Implantologist, Continental Hospitals, Hyderabad, India

DOI: [10.36348/SJODR.2019.v04i10.002](https://doi.org/10.36348/SJODR.2019.v04i10.002)

| Received: 04.10.2019 | Accepted: 11.10.2019 | Published: 17.10.2019

*Corresponding author: Dr. Abbasi Begum Meer Rownaq Ali

Abstract

The success of the treatment rendered depends on the accurate diagnosis and proper treatment planning based on the fundamental principles. The inception of CBCT into Implant dentistry, along with its wide range of application such as in the evaluation of TMJ, assessment of pathologies in or affecting the bones, 3D reconstructions of the bones or in the fabrication of a prosthetic components of the face and jaws in the complex maxillofacial reconstructions has led to a tremendous impact on the confidence of the dentist in the intricate procedures like sinus lifts, ridge augmentations, extractions, and implant placements. This article gives an insight into the background, indications and benefits of CBCT in Prosthodontics and Image Guided Implantology.

Keywords: Cone Beam Computed Tomography, Implant, Image Guided Implantology.

Copyright @ 2019: This is an open-access article distributed under the terms of the Creative Commons Attribution license which permits unrestricted use, distribution, and reproduction in any medium for non-commercial use (NonCommercial, or CC-BY-NC) provided the original author and source are credited.

INTRODUCTION

Placing an implant into an edentulous ridge requires meticulous comprehensive multiphase treatment planning and accurate execution of the treatment plan is based on the various diagnostic aids which include medical and dental history, thorough clinical evaluation, study models and radiographic examination [1, 2].

Accepted radiological protection principles such as ALARA should be used at all times and risk: benefit analysis should be carried out when making decisions on the choice of imaging for implant placement surgery. Although dental panoramic radiographs and periapical radiographs can be used for evaluating the site of implant placement, they suffer from inherent drawbacks of magnification, distortion, overlapping of structures and subsequent misrepresentation and inaccurate diagnosis [3]. It has been demonstrated that Panoramic radiography shows a magnification error in the range of 15–22% vertically as well as horizontally [4, 5]. In order to overcome these drawbacks of conventional radiographic technique, Cone-beam computerized tomography (CBCT) based on a cone-shaped X-ray beam centered on a two-dimensional (2D) detector is being used. It has an

excellent high-contrast resolution as a result of the small size and the geometry of its isotropic voxels which is equal in all three dimensions [3, 6, 7].

BACKGROUND

Computed Tomography (CT) was developed by Sir Godfrey Hounsfield five decades ago and also received a Nobel Prize along with A.M. Cormack for his achievement and gave his name to the measure of radiodensity known as Hounsfield Unit (HU) universally used in CT applications [8, 9, 10]. Medical multislice CT scanners used today are capable of performing a scan of the upper and/or lower jaw, and obtaining large volumes of data in few seconds, but due to certain drawbacks like the size and cost of the machines, the radiation exposure, the lack of familiarity and the need for a learning curve and training amongst dentists and the perceived cost/benefit ratio in patient care made them inappropriate for a dental office setting. CBCT was first introduced to dentistry in 1988 [11] and was first adapted for potential clinical use in 1982 at the Mayo Clinic Biodynamics Research Laboratory [11]. Although its initial applications was in angiography, exploration of CBCT technologies for use in radiation therapy guidance began in 1992 [12], followed by

integration of the first CBCT imaging system into the gantry of a linear accelerator in 1999 [13].

CBCT scanners for the oral and maxillofacial (OMF) region were pioneered in the late 1990s independently by Arai *et al.*, in Japan and Mozzo *et al.*, in Italy [14-17]. A patent application for the first commercially successful maxillofacial CBCT was made in Italy in 1995 with Attilio Tacconi and Piero Mozzo as co-inventors and the system was designed and produced by QR, Inc. of Verona which is now known as Cefla company [18]. The cone-shaped beam rotates 360° around the patient and is capable of producing hundreds of 2D images of a defined anatomical volume which are reconstructed into a voxel (digital) volume for visualization and analysis using a variation of the algorithm developed by Feldkamp in 1994 [19, 20]. Although earlier machines were larger than those currently available, they did offer advantages of producing good 3D images at lower radiation doses, and the footprint of the machines were suitable and small enough to fit into a dental office.

Indications of CBCT in Prosthodontics

CBCT has greater application in Prosthodontics viz. Implant prosthodontics, Temporomandibular joint (TMJ) imaging, Maxillofacial prosthodontics, Craniofacial and airway analysis and Comprehensive treatment planning in over denture patients [21].

CBCT Application in Implantology

One of the cardinal rules in implantology is that the implant placement surgery should be prosthetically driven [22], which means that implants should be planned keeping the final results in mind before beginning with the surgery and thus the final prosthetic structure is considered as the starting point in planning the treatment from both functional as well as aesthetic point of view [20, 23-25, 57]. Adequate assessment of the proposed site for implant placement should be done for the protection of the critical structures like the maxillary sinuses, incisive canal, mandibular canal and mental foramen as well as to characterize the alveolar bone morphology. It has been observed that CBCT provides accurate information regarding the bone width, height, quality of the bone and relationship to the critical anatomical structures. This in turn enables the implantologist to plan accurately the number, size, dimensions, type and positioning of the implants, and if necessary

augmentation procedures to be planned appropriately before beginning with the treatment [24]. Figure 1 to 5 demonstrates the clinical application of CBCT in identification of critical anatomical structures, available bone, preferred angulation of implant and nerve tracing. Several research studies have also shown that CBCT accurately detects differences in the loop length and diameter of mandibular canals in the interforaminal region, and also suggested that a large variations in these structures occur from one individual to another [11]. CBCT is also used in post-operative evaluation to assess the bone graft and implant position in the oral cavity [26, 27], thus making it an excellent imaging modality for planning implant placement [21, 28, 29].

Lower cost, smaller size and smaller radiation dose, easy availability for dentomaxillofacial examinations compared with Multi slice computed tomography (MSCT) are the key benefits of CBCT. It has been reported in the literature that CBCT provides substantial dose reduction of between 98.5% and 76.2% [3, 52-54]. It has excellent high-contrast resolution as a result of the Small size [3] and the geometry of its isotropic voxels is equal in all three dimensions. Thus, providing a resolution which often exceeds the resolution given by the highest grade MSCT.

The most important benefit of CBCT is that it provides the clinician with an interactive capability for real-time dimensional assessment. Studies have suggested that using 3D template as a drill guide fabricated using the CBCT imaging modality, during implant placement was highly reliable and predictable in terms of protection of important anatomical structures as well as in positioning of the implants [40]. High precision in planning and placement of implants has been made possible with the tremendous evolution in CBCT hardware and software, while minimizing the associated risks [55]. It provides information in all the 3 axes X,Y and Z, allows software manipulation and data visualization so that implants can be planned, avoiding vital structures and keeping them situated within the available bone [56]. In one of the study conducted by Timock AM *et al.*, to investigate the accuracy and reliability of buccal alveolar bone height and thickness measurements derived from CBCT images, it was concluded that CBCT can be used to quantitatively assess buccal bone height and buccal bone thickness with high precision and accuracy [20, 39].

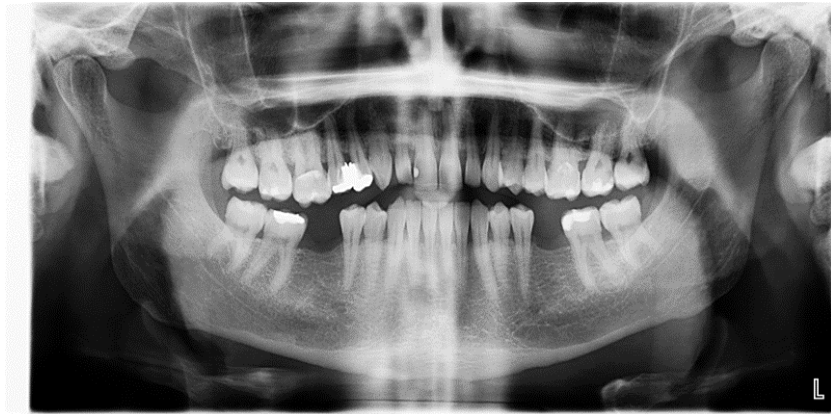

Fig-1: Initial assessment with 2D OPG

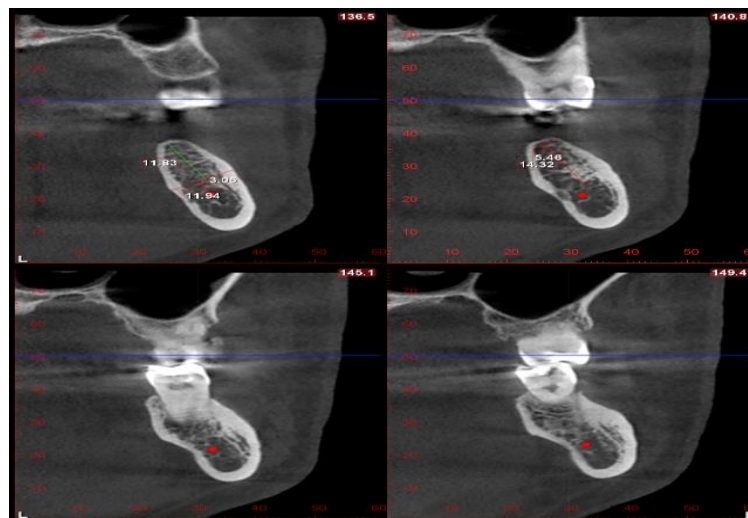


Fig-2: Coronal section (Left side) showing bucco-lingual dimension with special attention to the lingual concavity and preferred angulation of implant

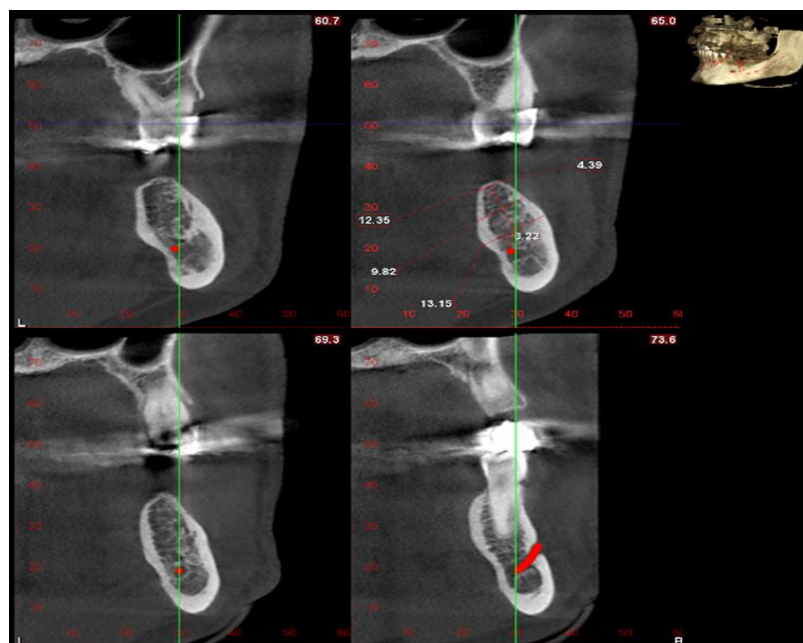


Fig-3: Coronal section (right side) critical distance is measured from the inferior alveolar canal with mental nerve localization

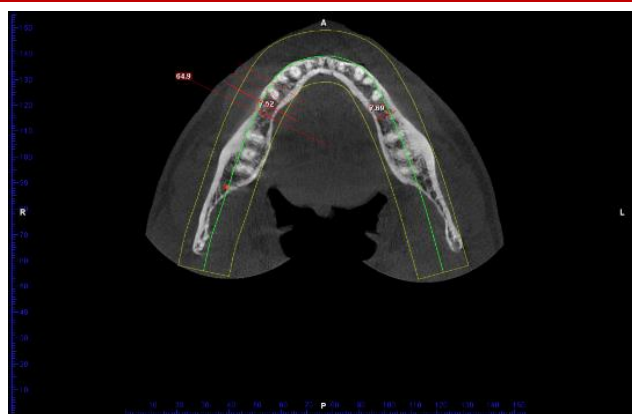

Fig-4: Axial section - buccolingual width – mesiodistal assessment

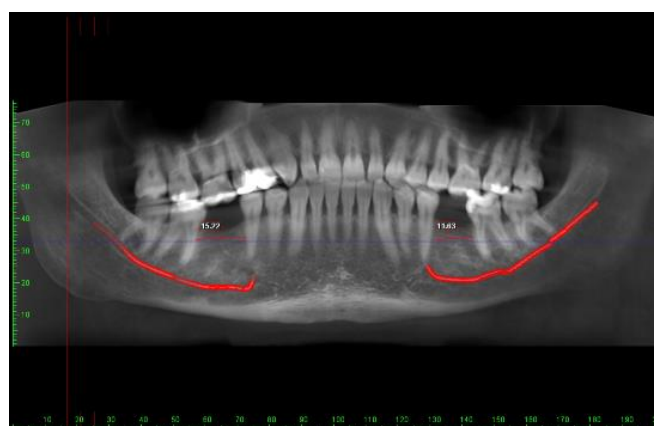


Fig-5: Nerve tracing with estimation of the available mesio-distal distance from a reconstructed 2D image from the CBCT scan

Image Guided Implantology

Placement of the implant via computer assisted surgery can be either through static or dynamic system. A static system uses CT generated CAD-CAM stents for implant placement. Dynamic navigation/guidance system uses a stereotactic tracking system to dynamically guide the surgeon's instruments to the correct location [20, 61, 62].

A CBCT scan, in combination with surgical planning software to produce a CAD/CAM surgical template, can be used as a virtual planning environment to recapitulate the ideal placement of the prosthetics, occlusion and associated supporting implants, in a virtual environment [20]. The computer-based Implantology involves virtual planning using CBCT of the associated jaw and radiographic stent called the Dual scan technique, which helps in deciding the most appropriate implant position with respect to anatomical structures and thereby the prosthetic outcome [25, 56-58]. CBCT guided implant planning allows evaluation and visualization of complex anatomy and guides the surgeon if there is a need for any tissue augmentation. In one of the study conducted to compare accuracy of two commercially available systems for image-guided dental implant insertion based on infrared tracking cameras and manual implantation it was concluded that image-guided insertion of dental implants is

significantly more accurate than manual insertion [55]. In another study conducted by Yatzkair G *et al.*, to evaluate the accuracy of computer-guided implantation in a human cadaver model, it was concluded that guided implantation can be used safely with a margin of error of 1 mm [59].

Emery RW *et al.*, conducted a model based research to evaluate the accuracy of Dynamic Navigation for Dental Implant placement and concluded that the angular and positional accuracy of implants delivered using the tested device was slightly higher for edentulous case types compared with the dentulous cases, measured relative to the preoperative implant plan.[60] A study had been conducted in the recent years by Michael S. Block *et al* to determine platform and angle accuracy for dental implants using dynamic navigation. The results of the study had shown that the accuracy of dynamic navigation was superior compared to free hand implant placement and it was concluded that Dynamic navigation could achieve accuracy of implant placement similar to static guides and was an improvement over freehand implant placement. In addition, there was a learning curve to achieve proficiency [61, 62].

ADVANTAGES OF DYNAMIC NAVIGATION

- Dynamic navigation is less invasive and minimizes the size of the incision and thus eliminating the need for tissue reflection for bone visualization.
- Dynamic navigation is more flexible as it allows for real-time modifications of the surgical plan when clinically indicated.
- It allows for provisional restorations to be fabricated prior to surgery which in turn allows for immediate restoration of implants.
- Direct visualization of the surgical field at all times.
- It ensures appropriate spacing of the implants from the teeth and provides accuracy in maintaining the appropriate space between the implants.
- There is no static guide interfering with visualization of the drill site.
- Dynamic navigation has greater advantage in patients with limited mouth opening and in the posterior area of the mouth such as the second molar sites.
- Implant size is not limited with dynamically guided systems as they are with static guides.
- CBCT scan, planning of the implant position, and placement of the implant can be done on the same day under computer-assisted guidance which in turn saves patients time as well as productivity of the clinician.
- Allows for improved surgeon ergonomics during surgery as, the navigation screen is used to guide the drilling, with minimal direct visualization of the drill in the patient's mouth.

Dynamic navigation with its numerous benefits can be utilized to the maximum only after understanding that, a learning curve is required to gain proficiency which would require additional time for training, simulation, and practice on a manikin. Comparison between static guide and dynamic navigation system has been illustrated in Table-1.

Table-1: Comparison between Static Guide and Dynamic Navigation System

S. No	STATIC GUIDE SYSTEM	DYNAMIC GUIDE SYSTEM
1	Implants placed using the CT generated guide stents fabricated using CAD-CAM	Uses optical technologies to track the patient and the hand piece and to display images onto a monitor
2	The implant position is dependent on the stent without the ability to change the implant position	Allows for real-time modification of surgical plan when clinically indicated
3	Fabrication of the imaging guide requires laboratory work before scanning , which will necessitate time delays and additional cost to the team and hence added cost to the patient	CBCT scan, planning of the implant position, and placement of implant can be done on the same day under computer- assisted guidance which in turn saves patients time as well as productivity of the clinician.
4	Static guide interferes with the visualization of the operating site	No static guide interference with the visualization of the drill site
5	More time consuming due to laboratory work involved	Less time consuming
6	Difficult to use in patients with limited mouth opening and in posterior region	Can be used in patients with limited mouth opening and posterior area of the mouth

CBCT application in fabrication of Surgical guides

With the advent of CBCT the fabrication of guide templates and its usage in implant placement has made the accurate positioning of the implant possible. Several studies have suggested CBCT to be the most appropriate three-dimensional method [24, 30-33]. Surgical guides offer several advantages over the conventional techniques including proper angulation, implant positioning relative to one another, eliminating the need for development of radiological template, more precise with respect to the intended position, angulation and depth of the osteotomy.[24, 34-40] They are manufactured with computer-aided design & computer-aided manufacturing (CAD-CAM) using the 3 Dimensional images of CBCT combined with intraoral scanners like Cerec Omnicam or Cerec Bluecam [21] to obtain the 3 dimension virtual replicas which in turn is used to fabricate the surgical guide with CAD software.

Application of CBCT in Temporomandibular Joint

CBCT is considered as the most useful diagnostic aid in TMJ imaging. An important advantage

of CBCT imaging of TMJ is that it allows accurate measurements of the volume and surface of the condyle. These measurements are extremely advantageous in clinical practice when treating patients with TMJ dysfunction.

Osteoarthritis of the TMJ is an age related degenerative disease seen in almost 40% of patients above the age of 40 years. It causes bony changes in the TMJ like flattening, sclerosis, formation of osteophytes, erosion, resorption of the condylar head, erosion of the mandibular fossa and reduced joint space. Flattening (59%) and osteophyte (29%) are the most prevalent degenerative changes seen on CBCT.

Alkhader *et al.*, performed a comparative study between CBCT and MRI [42]. According to them CBCT is better than MRI in detecting changes in shape (flattening, osteophyte formation or erosion) rather than changes in size. They concluded that this was probably because MRI had limited spatial resolution and increased slice thickness (>3mm) in clinical use.

CBCT plays an important role in diagnosing early stages of juvenile idiopathic arthritis (JIA) in children which, when undetected, can damage facial development and cause growth alterations. Farronato *et al.*, concluded from their study that CBCT can be used to volumetrically quantify the TMJ damage in these patients by measuring condylar and mandibular volumes [43]. Condylar asymmetry is very common in children with JIA. CBCT shows a wide variety of condylar destruction patterns which could be small erosions within the cortex to almost complete deformation of the head of the condyle.

Studies conducted by Marques *et al* and Patel *et al.*, suggested that the sensitivity for detecting condylar osseous defects using CBCT was fairly high i.e around 72.9–87.5% [41-45]. It was also suggested that erosion of the condylar surface may be easier to detect from CBCT images than other morphologic changes [46] and high detectability of erosive changes of condyle by CBCT was confirmed [46, 47]. Studies also suggest that CBCT can be considered the method of choice for the assessment of cortical bone details of the TMJ because of the multiplanar reformation capabilities and high spatial resolution [46, 48].

In one of the study conducted by Mu-Qing Liu *et al* CBCT was used as tool for assessing the condylar remodeling accompanying anterior repositioning splint therapy in patients with temporomandibular joint disk displacement. The presence of “double contour” images after splint therapy was confirmed in 3 dimensions with the use of CBCT. Double contour images are considered to be the result of adaptive bone remodeling arising from change of stresses in the articular space. In view of its increasing availability, lower radiation dosage and diagnostic reliability, CBCT is becoming the imaging technique of choice for evaluating and monitoring osseous changes in the TMJs [49]. It has become the imaging of choice in cases of trauma, pain and dysfunction, and fibro-osseous ankylosis, as well as in the detection of condylar cortical/sub-cortical erosion, and cysts [17, 20, 21]. Larheim TA *et al.*, concluded in their study that CBCT had emerged as a cost- and dose-effective alternative to CT for examination of the TMJs, and is also superior to

conventional radiographic methods, as well as MRI, in the assessment of osseous TMJ abnormalities [46].

CBCT in Maxillofacial Reconstruction

CBCT DICOM data is used successfully to obtain the three-dimensional augmented virtual models of the patient's face, bony structures, and dentition for treatment planning [43]. It has been shown that obturators can also be precisely milled using larger CAD/CAM units making the cumbersome procedure of fabricating an obturators a much easier task [21]. CBCT with its accuracy in measurement of osseous structures along with CAD/CAM and rapid prototyping helps in planning for grafting/reconstructing the implant site and placing implants in a more precise manner, and thus improving the surgeon's communication with maxillofacial prosthodontists which perhaps accounts for the improvement of implant survival rates, especially in the nasal and orbital areas, and the reduction of complications [50]. The digital application also facilitates the fabrication of prostheses [50]. Ariani N *et al.*, in their study has observed that using CBCT by superimposing preoperative and post operative CBCT data, assessment of accuracy of digitally planned implants can be made. Slight variation between the planned and actual implant position was seen, however, these changes were minor and the implant positions were more satisfactory from both surgical and prosthodontic point of view [38, 51].

Apart from these applications, CBCT is found to be useful in determining the number and morphology of roots, the type and degree of root angulation as well as visualize buccal and lingual morphological bone defects. This in turn can serve as an important adjunct in the rehabilitation of complex full mouth rehabilitation cases, particularly when multiple teeth and bony areas needs to be assessed [20].

Limitations of CBCT

Although CBCT has obvious advantages over 2D radiography there are some inherent limitations as well. They are summarized in Table-2. Many new CBCT units contain flat-panel detectors that are less prone to beam hardening artifacts, so they are able to provide more detailed information.

Table-2: Limitations of CBCT

S. No	LIMITATIONS OF CBCT	REFERENCES
1	Susceptible to motion artifacts and beam hardening around dense objects.	Rodrigues SJ <i>et al.</i> , 2014 [20]
2	Limited contrast resolution mainly attributed to high scatter radiation during image acquisition and inherent flat panel detector related artifacts.	Gopal S 2017 [28] Rodrigues SJ <i>et al.</i> , 2014 [20] Orentlicher G <i>et al.</i> , 2011 [22]
3	A limited ability to visualize internal soft tissues.	Gopal S 2017 [28] Rodrigues SJ <i>et al.</i> , 2014 [20]
4	Limited detector size causes limited field of view and limited scanned volume	De Vos <i>et al.</i> , 2009 [8]
5	Increased noise from scatter radiation and concomitant loss of contrast resolution	De Vos <i>et al.</i> , 2009 [8]
6	Cannot be used for estimation of Hounsfield units (HU)	De Vos <i>et al.</i> , 2009 [8]
7	Clarity of CBCT images is affected by different artifacts like; X-ray beam artifacts, Patient-related artifacts, Scanner-related artifacts, Cone beam-related artifacts etc.	Scarfe WC <i>et al.</i> , 2008 [3]

CONCLUSION

With an accurate 3D depiction of oral structures along with lower radiation exposure CBCT has become a gold standard in the field of dentistry especially in oral and maxillofacial reconstructions and in image guided implantology. Tremendous advances have been made which includes an overall reduction in radiation dose imparted by this technology, improved spatial resolution, and increased versatility of the software. Accurate preplanning requires information about the bone in all the 3 dimensions which can be achieved by using CBCT and also avoid the critical anatomical structures like the nerves and sinus in the area of the treatment planned for the placement of an implant. However, it is crucial to respect the radiological protection principle based on ALARA concept and use 3D CBCT judiciously as required and when clinically indicated on a case-by-case basis where it increases diagnostic knowledge and improves the patient's standard of dental care.

REFERENCES

- Misch, C. E. (2008). Contemporary Implant Dentistry, 3rd ed. St.Louis: Mosby.
- Mehrotra, G., Iyer, S., & Verma, M. (2009). Treatment planning in implant patient. *International Journal of clinical implant dentistry*, 1: 12-21.
- Scarfe, W. C., & Farman, A. G. (2008). What is cone-beam CT and how does it work?. *Dental Clinics of North America*, 52(4), 707-730.
- Gupta, S., Patil, N., Solanki, J., Singh, R., & Laller, S. (2015). Oral implant imaging: a review. *The Malaysian journal of medical sciences: MJMS*, 22(3), 7-17.
- Karjodkar, F. R. (2011). Implant Radiology. Text book of dental and maxillofacial radiology. 2nd ed. Jaypee, 881-928.
- Farman, A. G., & Scarfe, W. C. (2018). Historical perspectives on CBCT. In *Maxillofacial Cone Beam Computed Tomography* (pp. 3-11). Springer, Cham.
- Suomalainen, A., Esmacili, E. P., & Robinson, S. (2015). Dentomaxillofacial imaging with panoramic views and cone beam CT. *Insights into imaging*, 6(1), 1-16.
- De Vos, W., Casselman, J., & Swennen, G. R. J. (2009). Cone-beam computerized tomography (CBCT) imaging of the oral and maxillofacial region: a systematic review of the literature. *International journal of oral and maxillofacial surgery*, 38(6), 609-625.
- Dawood, A., Patel, S., & Brown, J. (2009). Cone beam CT in dental practice. *British dental journal*, 207(1), 23-28.
- Tischler, M., & Ganz, S. D. (2012). The CT/CBCT-based team approach to care. Part 2: communication with the surgeon to support the final prosthesis. *Dent Today*, 31, 108.
- Mah, J. (2014). The genesis and development of CBCT for dentistry, 1-12. www.ineedce.com.
- Cho, P. S., Johnson, R. H., & Griffin, T. W. (1995). Cone-beam CT for radiotherapy applications. *Physics in Medicine & Biology*, 40(11), 1863-1883.
- Jaffray, D. A., Drake, D. G., Moreau, M., Martinez, A. A., & Wong, J. W. (1999). A radiographic and tomographic imaging system integrated into a medical linear accelerator for localization of bone and soft-tissue targets. *International Journal of Radiation Oncology* Biology* Physics*, 45(3), 773-789.
- De Vos, W., Casselman, J., & Swennen, G. R. J. (2009). Cone-beam computerized tomography (CBCT) imaging of the oral and maxillofacial region: a systematic review of the literature. *International journal of oral and maxillofacial surgery*, 38(6), 609-625.
- Arai, Y., Tammisalo, E., Iwai, K., Hashimoto, K., & Shinoda, K. (1999). Development of a compact computed tomographic apparatus for dental use. *Dentomaxillofacial Radiology*, 28(4), 245-248.
- Mozzo, P., Procacci, C., Tacconi, A., Martini, P. T., & Andreis, I. B. (1998). A new volumetric CT machine for dental imaging based on the cone-beam technique: preliminary results. *European radiology*, 8(9), 1558-1564.
- Venkatesh, E., & Elluru, S. V. (2017). Cone beam computed tomography: basics and applications in dentistry. *Journal of Istanbul University Faculty of Dentistry*, 51(3 Suppl 1), 102-121.
- Farman, A. G., & Scarfe, W. C. (2018). Historical perspectives on CBCT. In *Maxillofacial Cone Beam Computed Tomography* (pp. 3-11). Springer, Cham.
- Feldkamp, L. A., Davis, L. C., & Kress, J. W. (1984). Practical cone-beam algorithm. *Josa a*, 1(6), 612-619.
- Rodrigues, S. J., Mundathaje, M., Raju, M., & Qureshi, S. (2014). Three Dimensional Imaging in Implant Assessment for the Prosthodontist-Utilization of the Cone Beam Computed Tomography. *International Journal of Prosthodontics and Restorative Dentistry*, 4(1), 23-33.
- John, G. P., Joy, T. E., Mathew, J., & Kumar, V. R. (2016). Applications of cone beam computed tomography for a prosthodontist. *The Journal of the Indian Prosthodontic Society*, 16(1), 3-7.
- Orentlicher, G., & Abboud, M. (2011) Guided Surgery for Implant Therapy. *Dental Clin N Am*, 15: 557-744.
- Adell, R., Eriksson, B., Lekholm, U., Brånemark, P. I., & Jemt, T. (1990). A long-term follow-up study of osseointegrated implants in the treatment of totally edentulous jaws. *International Journal of Oral & Maxillofacial Implants*, 5(4), 347-359.

24. Borisov, R. (2016). Radiological templates and CAD/CAM surgical guides. A literature review. *Journal of IMAB-Annual Proceeding (Scientific Papers)*, 22(3), 1285-1295.
25. Kochhar, A., & Ahuja, S. (2015). Computer Guided Implantology: For Optimal Implant Planning. *Dent Implants Dentures*, 1, 101.
26. Nodehi, D., Pahlevankashi, M., Moghaddam, M. A., & Nategh, B. (2015). Cone beam computed tomography functionalities in dentistry. *International Journal Contemp Dent Med Rev*, 2015, 1-8.
27. Madhav, V. N. V. (2011). Cone Beam Computed Tomography In Implantology. *Indian Journal of Dental Sciences*, 3(5): 10-15.
28. Saraswathi Gopal, K. (2017). CBCT A Novel Imaging Technique in Dentistry—A Recent Update. *International Journal of Information Research and Review*, 4: 3911-3915.
29. Worthington, P., Rubenstein, J., & Hatcher, D. C. (2010). The role of cone-beam computed tomography in the planning and placement of implants. *The Journal of the American Dental Association*, 141, 19S-24S.
30. Elhayes, K., & Eldin, M. A. (2012). Calibration of new software with cone beam ct for evaluation of its reliability in densitometric analysis around dental implants. *Life Sci J*, 9(2), 61-7.
31. Figliuzzi, M., Mangano, F., & Mangano, C. (2012). A novel root analogue dental implant using CT scan and CAD/CAM: selective laser melting technology. *International journal of oral and maxillofacial surgery*, 41(7), 858-862.
32. Chan, H. L., Misch, K., & Wang, H. L. (2010). Dental imaging in implant treatment planning. *Implant dentistry*, 19(4), 288-298.
33. Chadwick, J. W., & Lam, E. W. (2010). The effects of slice thickness and interslice interval on reconstructed cone beam computed tomographic images. *Oral Surgery, Oral Medicine, Oral Pathology, Oral Radiology, and Endodontology*, 110(4), e37-e42.
34. Block, M. S., & Emery, R. W. (2016). Static or dynamic navigation for implant placement—choosing the method of guidance. *Journal of Oral and Maxillofacial Surgery*, 74(2), 269-277.
35. Silver, M. D., Yahata, M., Saito, Y., Sivers, E. A., Huang, S. R., Drawert, B. M., & Judd, T. C. (1992, June). Volume CT of anthropomorphic phantoms using a radiation therapy simulator. In *Medical Imaging VI: Instrumentation* (Vol. 1651, pp. 197-211). International Society for Optics and Photonics.
36. Scherer, U., Stoetzer, M., Ruecker, M., Gellrich, N. C., & von See, C. (2015). Template-guided vs. non-guided drilling in site preparation of dental implants. *Clinical oral investigations*, 19(6), 1339-1346.
37. Pozzi, A., Tallarico, M., Marchetti, M., Scarfò, B., & Esposito, M. (2014). Computer-guided versus free-hand placement of immediately loaded dental implants: 1-year post-loading results of a multicentre randomised controlled trial. *Eur J Oral Implantol*, 7(3), 229-242.
38. Van der Meer, W. J., Vissink, A., Raghoobar, G. M., & Visser, A. (2012). Digitally designed surgical guides for placing extraoral implants in the mastoid area. *International Journal Oral Maxillofac Implants*, 27(3), 703-707.
39. Timock, A. M., Cook, V., McDonald, T., Leo, M. C., Crowe, J., Benninger, B. L., & Covell Jr, D. A. (2011). Accuracy and reliability of buccal bone height and thickness measurements from cone-beam computed tomography imaging. *American journal of orthodontics and dentofacial orthopedics*, 140(5), 734-744.
40. Nickenig, H. J., & Eitner, S. (2007). Reliability of implant placement after virtual planning of implant positions using cone beam CT data and surgical (guide) templates. *Journal of Cranio-Maxillofacial Surgery*, 35(4-5), 207-211.
41. Patel, A., Tee, B. C., Fields, H., Jones, E., Chaudhry, J., & Sun, Z. (2014). Evaluation of cone-beam computed tomography in the diagnosis of simulated small osseous defects in the mandibular condyle. *American Journal of Orthodontics and Dentofacial Orthopedics*, 145(2), 143-156.
42. Alkhader, M., Ohbayashi, N., Tetsumura, A., Nakamura, S., Okochi, K., Momin, M. A., & Kurabayashi, T. (2010). Diagnostic performance of magnetic resonance imaging for detecting osseous abnormalities of the temporomandibular joint and its correlation with cone beam computed tomography. *Dentomaxillofacial Radiology*, 39(5), 270-276.
43. Farronato, G., Garagiola, U., Carletti, V., Cressoni, P., Mercatali, L., & Farronato, D. (2010). Change in condylar and mandibular morphology in juvenile idiopathic arthritis: cone beam volumetric imaging. *Minerva Stomatol*, 59(10), 519-534.
44. Marques, A. P., Perrella, A., Arita, E. S., Pereira, M. F. S. D. M., & Cavalcanti, M. D. G. P. (2010). Assessment of simulated mandibular condyle bone lesions by cone beam computed tomography. *Brazilian oral research*, 24(4), 467-474.
45. Singh, I., & Soin, A. (2017). Cone-beam computed tomography-A boon to dentistry. *International Journal Advanced Research*, 5: 578-583.
46. Larheim, T. A., Abrahamsson, A. K., Kristensen, M., & Arvidsson, L. Z. (2014). Temporomandibular joint diagnostics using CBCT. *Dentomaxillofacial Radiology*, 44(1), 20140235.
47. Katakami, K., Shimoda, S., Kobayashi, K., & Kawasaki, K. (2008). Histological investigation of osseous changes of mandibular condyles with

- backscattered electron images. *Dentomaxillofacial Radiology*, 37(6), 330-339.
48. Ahmad, M., Hollender, L., Anderson, Q., Kartha, K., Ohrbach, R., Truelove, E. L., ... & Schiffman, E. L. (2009). Research diagnostic criteria for temporomandibular disorders (RDC/TMD): development of image analysis criteria and examiner reliability for image analysis. *Oral Surgery, Oral Medicine, Oral Pathology, Oral Radiology, and Endodontology*, 107(6), 844-860.
49. Liu, M. Q., Chen, H. M., Yap, A. U. J., & Fu, K. Y. (2012). Condylar remodeling accompanying splint therapy: a cone-beam computerized tomography study of patients with temporomandibular joint disk displacement. *Oral surgery, oral medicine, oral pathology and oral radiology*, 114(2), 259-265.
50. Bencharit, S. (2012). Challenges and prospective applications of extra-oral implants for maxillofacial rehabilitation. *Anaplastology*, 1, e103.
51. Ariani, N., Visser, A., Van Oort, R. P., Kusdhany, L., Rahardjo, T. B., Krom, B. P., ... & Vissink, A. (2013). Current state of craniofacial prosthetic rehabilitation. *Int J Prosthodont*, 26(1), 57-67.
52. Schulze, D., Heiland, M., Thurmann, H., & Adam, G. (2004). Radiation exposure during midfacial imaging using 4-and 16-slice computed tomography, cone beam computed tomography systems and conventional radiography. *Dentomaxillofacial Radiology*, 33(2), 83-86.
53. Scaf, G., Lurie, A. G., Mosier, K. M., Kantor, M. L., Ramsby, G. R., & Freedman, M. L. (1997). Dosimetry and cost of imaging osseointegrated implants with film-based and computed tomography. *Oral Surgery, Oral Medicine, Oral Pathology, Oral Radiology, and Endodontology*, 83(1), 41-48.
54. Dula, K., Mini, R., van der Stelt, P. F., Lambrecht, J. T., Schneeberger, P., & Buser, D. (1996). Hypothetical mortality risk associated with spiral computed tomography of the maxilla and mandible. *European Journal of Oral Sciences*, 104(5-6), 503-510.
55. Worthington, P., Rubenstein, J., & Hatcher, D. C. (2010). The role of cone-beam computed tomography in the planning and placement of implants. *The Journal of the American Dental Association*, 141, 19S-24S.
56. Kurtzman, G. M., & Dompkowski, D. F. (2011). Benefits of CBCT in Implant planning. *International Journal of Oral Implantology and Clinical Research*, 2: 31-35.
57. Brief, J., Edinger, D., Hassfeld, S., & Eggers, G. (2005). Accuracy of image-guided implantology. *Clinical Oral Implants Research*, 16(4), 495-501.
58. Katsoulis, J., Pazera, P., & Mericske-Stern, R. (2009). Prosthetically driven, computer-guided implant planning for the edentulous maxilla: a model study. *Clinical Implant Dentistry and Related Research*, 11(3), 238-245.
59. Yatzkair, G., Cheng, A., Brodie, S., Raviv, E., Boyan, B. D., & Schwartz, Z. (2015). Accuracy of computer-guided implantation in a human cadaver model. *Clinical oral implants research*, 26(10), 1143-1149.
60. Emery, R. W., Merritt, S. A., Lank, K., & Gibbs, J. D. (2016). Accuracy of dynamic navigation for dental implant placement—model-based evaluation. *Journal of Oral Implantology*, 42(5), 399-405.
61. Block, M. S., & Emery, R. W. (2016). Static or dynamic navigation for implant placement—choosing the method of guidance. *Journal of Oral and Maxillofacial Surgery*, 74(2), 269-277.
62. Block, M. S., Emery, R. W., Lank, K., & Ryan, J. (2017). Implant Placement Accuracy Using Dynamic Navigation. *International Journal of Oral & Maxillofacial Implants*, 32(1): 92-99.