

Post-traumatic False Aneurysm of the Aortic Isthmus Revealed by Ortner's Syndrome

Bakzaza O^{1*}, El aquaoui M¹, Nador K¹

¹Assistant Professor of Vascular Surgery, Faculty of Medicine and Pharmacy of Fes, Department of Vascular Surgery Moulay Ismail Military Hospital, Sidi Moumen Ben Abdellah University, Fez

²Vascular Surgeon, Faculty of Medicine and Pharmacy of Marrakech

³Departement of Otolaryngology and Cervico-facial Surgery, Moulay Ismail Militaire Hospital, Faculty of Medicine and Pharmacy of Fez, Sidi Moumen Ben Abdellah University, Fez

DOI: [10.36348/sjm.2022.v07i05.012](https://doi.org/10.36348/sjm.2022.v07i05.012)

| Received: 13.04.2022 | Accepted: 10.05.2022 | Published: 26.05.2022

*Corresponding Author: Bakzaza Oualid

Assistant Professor of Vascular Surgery, Faculty of Medicine and Pharmacy of Fes, Department of Vascular Surgery Moulay Ismail Military Hospital, Sidi Moumen Ben Abdellah University, Fez

Abstract

Introduction: Left vocal cord palsy by Compression of the left recurrent nerve by the left atrium in tight mitral stenosis defines Ortner's cardio-vocal syndrome. The vascular etiology of compression thoracic aortic aneurysm is well described in the literature. Left vocal cord palsy by Compression of the left recurrent nerve by the left atrium in tight mitral stenosis defines Ortner's cardio-vocal syndrome. The vascular etiology of compression thoracic aortic aneurysm is well described in the literature. **Case Record:** We present the case of an 80-year-old man with a history of thoracic trauma and recent onset dysphonia and simultaneous discovery of an aortic isthmus pseudoaneurysm and left vocal cord paralysis. **Discussion:** The place of dysphonia during post traumatic false aneurysm of the aortic isthmus is commented. This observation documents the mechanism of compression of the recurrent left nerve by a post-traumatic false aneurysm of the thoracic aorta. Adequate management can improve the patient's prognosis and quality of life.

Keywords: Chest Trauma, False Aortic Isthmus aneurysm, Dysphonia.

Copyright © 2022 The Author(s): This is an open-access article distributed under the terms of the Creative Commons Attribution **4.0 International License (CC BY-NC 4.0)** which permits unrestricted use, distribution, and reproduction in any medium for non-commercial use provided the original author and source are credited.

INTRODUCTION

Cardiovascular syndrome or Ortner syndrome corresponds to paralysis of the left recurrent nerve of cardiovascular origin. In 1897, N. Ortner described the first case of dysphonia secondary to compression of the left recurrent nerve by the left atrium in the tight mitral stenosis [1]. Since this description, the etiological framework has been extended to other compressive causes, in particular aortic aneurysm [2, 3]. We report a case of Ortner's syndrome following a post-traumatic aneurysm of the aortic isthmus.

CLINICAL CASE

An 80-year-old farmer by profession; Having as a history, a thoracic trauma with left clavicle fracture 2 years ago following an AVP, without other ATCDS of inflammatory or cancerous pathologies or toxic habit. He presented for dysphonia of recent installation (3 months) In whom the clinical examination finds: A patient in good general condition, well oriented in time and space, hemodynamically and respiratory stable While the ENT examination showed paralysis of the left vocal cord on laryngoscopy, with no other associated signs. The neurological examination shows no sign in favor of damage to the cranial nerves (X or XI). An etiological assessment of the dysphonia revealed: a false aneurysm at the level of the aortic isthmus on CT angiography (Figure 1).

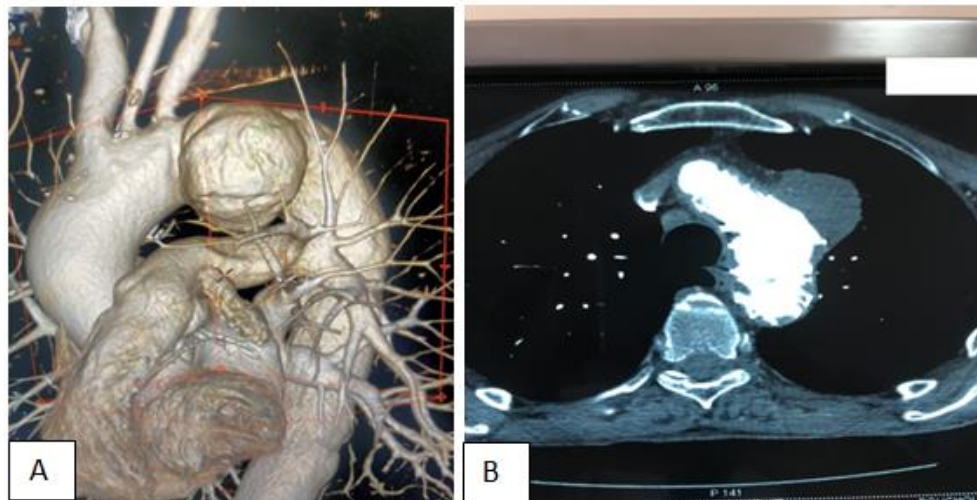


Fig-1: A: sagittal images of the thoracic aorta in 3D reconstruction Showing a pseudoaneurysm (arrowhead) in the aortic isthmus. B: Thoracic CT in axial incidence showing a pseudoaneurysm of the thoracic aorta at the level of the aortic isthmus

The patient was referred to our training for additional care. According to a multidisciplinary medical consultation, interventional care was offered to the patient.

The patient benefited from the placement of an endovascular prosthesis with reimplantation of the

artery under the left keyboard at the level of the left common carotid artery. (Figure 2) simple post-op follow-up. The patient was declared discharged on day 7 post-operative; he benefited from additional ENT and Speech Therapy care, with a gradual recovery of his normal pat.

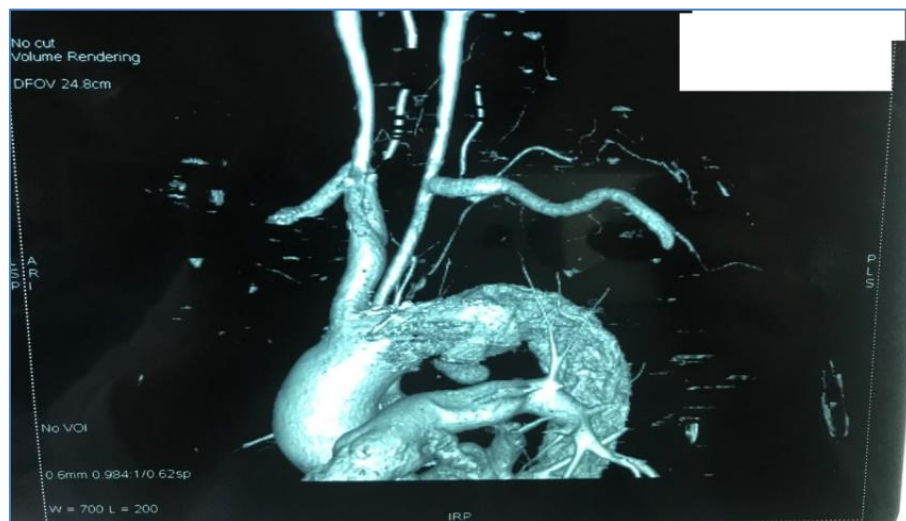


Fig-2: CT angiography of control: exclusion of the false aneurysm, with a permeable carotid-subclavian bypass

DISCUSSION

Involvement of the left recurrent nerve of cardiovascular origin defines Ortner's syndrome. The association of thoracic aortic aneurysm and Ortner syndrome is rare, less than 5% of thoracic aortic aneurysms are associated with left recurrent nerve palsy [4].

Dysphonia by recurrent paralysis has been reported during Horton's disease in the context of Vernet's syndrome which associates simultaneous and unilateral damage to the IX, X and XI nerves, attributed

to ischemia of the ascending pharyngeal artery, branch of the external carotid artery [5].

In our patient, there was no other abnormality on the ENT examination in favor of damage to the cranial nerves. In our observation, the false aneurysm located at the arch of the aorta at the level of the isthmus can explain the dysphonia through compression of the recurrent nerve during its mediastinal course, thus corresponding to the cardiovocal syndrome [1-3].

Imaging provides diagnostic guidance. CT angiography is the examination of choice, it allows the diagnosis of aneurysms, to guide the etiological diagnosis and to look for complications [6]. CT angiography also allows reconstructions which remain useful in the context of pre-therapeutic assessment [6].

The etiologies of the cardiovascular syndrome found in the literature are: dilation of the left atrium on tight mitral stenosis, and aortic aneurysms. These aneurysms are in most cases atheromatous in nature [7]. In our case there is no sign in favor of these pathologies described in the literature; we can retain the most probable etiology a post-traumatic false aneurysm given the history of thoracic trauma in our patient.

Aortic lesions, in particular isthmus ruptures, are the most common vascular lesions in blunt chest trauma. They constitute a particular clinical entity, for which significant progress has been made in the field of diagnosis and treatment [8].

In 1958, Parmley proposed a classification of traumatic vascular lesions, based on autopsy findings: False aneurysms by rupture under adventitia are classified (D) [9].

Spontaneous evolution is generally fatal, but management of the false aneurysm has made it possible to observe a favorable evolution with regression of the dysphonia [10]. Progressive recovery of the normal pathway observed in our patient.

Surgical treatment by thoracotomy allows, in addition to treatment of the aneurysm, the release and unwinding of the left recurrent nerve with recovery from the paralysis [11].

Our patient underwent end-vascular treatment with a Graft stent Under general anesthesia with surgical approach to the common femoral artery.

CONCLUSION

Our observation of a post-traumatic false aneurysm of the isthmus of the aorta revealed by Ortner's syndrome suggests adding post-traumatic aortic false aneurysm to the list of etiologies of Ortner's cardio-vocal syndrome. Thus, end-vascular

management helps prevent fatal complications and contributes to symptomatic improvement and the patient's quality of life.

REFERENCES

1. Ortner, N.I. (1897). Recurrenslähmung bei Mitralstenose. *Wien KlinWochenschr*, 10; 753–5.
2. Annema, J.T., Brahim, J.J., Rabe, K.F. (2004). A rare case of Ortner's syndrome (cardiovascular hoarseness). *Thorax*, 59; 636.
3. Slater, B.G., Sohaib, S.A., Armstrong, P. (1999). A case of hoarse voice. *Br J Radiol*, 72; 1133–4.
4. Teixido, M.T., Leonetti, J.P. (1990). Recurrent laryngeal nerve paralysis associated with thoracic aortic aneurysm. *Otolaryngol Head Neck Surg*, 102; 140–4.
5. Gout, O., Viala, K., Lyon-Caen, O. (1998). Giant cell arteritis and Vernet's syndrome. *Neurology*, 50; 1862–4.
6. Righini, C. A., Nadour, K., & Reyt, E. (2013). Dysphonie révélatrice d'une pathologie rare. *Annales françaises d'Oto-rhino-laryngologie et de Pathologie Cervico-faciale*, 130(2), 108–111.
7. Chan, P., Huang, J. J., & Yang, Y. J. (1994). Left vocal cord palsy: an unusual presentation of a mycotic aneurysm of the aorta caused by *Salmonella choleraesuis*. *Scandinavian journal of infectious diseases*, 26(2), 219–221.
8. Goarin, J.P., T. (2001). Barbry Département d'anesthésie-réanimation, Pitié-Salpêtrière, 83, boulevard de l'Hôpital, 75651 Paris cedex 13, France (Reçu le 24 juillet 2001; accepté le 2 août 2001)
9. Soirée FMC du 5 novembre 2014 ;dr Delphine Gamondes ;service de radiologie diagnostique et thérapeutique GHE-LYON. rupture traumatique de l'isthme aortique
10. Stoob, K., Alkadhi, H., Wildermuth, S., Lachat, M., & Pfammatter, T. (2004). Resolution of hoarseness after endovascular repair of thoracic aortic aneurysm: a case of Ortner's syndrome. *Annals of Otolaryngology, Rhinology & Laryngology*, 113(1), 43–45.
11. Stoob, K., Alkadhi, H., Wildermuth, S., Lachat, M., & Pfammatter, T. (2004). Resolution of hoarseness after endovascular repair of thoracic aortic aneurysm: a case of Ortner's syndrome. *Annals of Otolaryngology, Rhinology & Laryngology*, 113(1), 43–45.