

Gastrointestinal Stromal Tumor of the Proximal Small Intestine Revealed by Hemorrhagic Shock: About 02 Cases and Review of the Literature

Sarra Bahja^{1*}, Hakima Abid¹, Nada Lahmidani¹, Mounia El Yousfi¹, Dafr Allah Benajah¹, Sidi Adil Ibrahim¹, Mohammed El Abkari¹, Amine EL Mekkaoui¹

¹Department of Gastroenterology, University Hospital Hassan II Fez, University Sidi Mohammed Ben Abdallah, Fes, Morocco

DOI: [10.36348/sjm.2022.v07i04.005](https://doi.org/10.36348/sjm.2022.v07i04.005)

| Received: 05.03.2022 | Accepted: 08.04.2022 | Published: 23.04.2022

*Corresponding Author: Sarra Bahja

Department of Gastroenterology, University Hospital Hassan II Fez, University Sidi Mohammed Ben Abdallah, Fes, Morocco

Abstract

Gastrointestinal stromal tumors are mesenchymal tumors that represent 0.1% to 0.3% of all malignant tumors. Their clinical presentation is nonspecific but presentation by massive hemorrhage with hemodynamic instability is rare. We report the cases of 02 young patients who presented a fulminant digestive hemorrhage with hemodynamic instability and whose endoscopic exploration did not reveal any obvious etiology. That's why we involved interventional radiology and surgical team in order to localize and confirm the diagnosis of a hemorrhagic jejunal GIST and then to ensure the hemostasis by small bowel resection taking away the jejunal tumor.

Keywords: Small Bowel GIST; hemorrhagic GIST.

Copyright © 2022 The Author(s): This is an open-access article distributed under the terms of the Creative Commons Attribution 4.0 International License (CC BY-NC 4.0) which permits unrestricted use, distribution, and reproduction in any medium for non-commercial use provided the original author and source are credited.

INTRODUCTION

Gastrointestinal stromal tumors (GISTs) are rare mesenchymal tumors arising from interstitial cells of Cajal of the gastrointestinal tract and characterized by KIT (CD117) protein expression [1]. First described by Mazur and Clark in 1983 [2], they represent only 0.1-3% of all neoplasms of the gastrointestinal tract with an estimated frequency of 10-20 per million population [3, 4].

Intermittent gastrointestinal bleeding secondary to necrosis and ulceration of the overlying mucosa is the most common manifestation of GIST (42%), but massive life-threatening bleeding requiring urgent surgical intervention is rare [5].

The aim of this work is to report two clinical cases of hemorrhagic shock secondary to jejunal GIST in two young patients who required multidisciplinary management and urgent hemostatic surgery.

CLINICAL CASE

Clinical Case N 1

A 28 year old female patient, without any notable clinical history, who presented with melena. The initial clinical examination found a pale patient;

hemodynamically stable; and the abdominal examination was normal.

A biological check-up was performed, showing a hemoglobin (Hb) of 10g/dl normocytic normochromic with a correct platelet count and a prothrombin rate (PT) of 76%.

A fibroscopy was performed within the first 24 hours, which revealed an erythematous gastritis without any bleeding stigmata in the stomach.

The evolution was marked by the installation of a hemodynamic instability with a blood pressure of 90/60 mmhg and a disturbance of consciousness with polypnea, a nasogastric probe was put in which did not show any blood coming from the stomach, A cell blood count was redone, showing a Hb of 3g/dl, so the patient was put on a high dose of noradrenaline and intubated, ventilated and sedated on neurological and respiratory criteria, with massive transfusion of red blood cells, platelet cells and fresh frozen plasma.

After a multidisciplinary discussion, the decision was made to perform an Angiography which did not reveal any obvious etiology or extravasation of

contrast medium. An urgent colonoscopy was performed after 6 hours, which revealed a significant ileal blood stasis with a normal colonic mucosa.

Therefore, the decision was made to do a diagnostic arteriography which showed a proximal left jejunal blush (★Figure 1) and following the confrontation with the preceding CT Angiography, a heterogeneous jejunal tumor process with a predominantly exophytic development was found, enhanced on arterial time, containing hypodense areas, measuring 25x22x10mm (Figure 2).

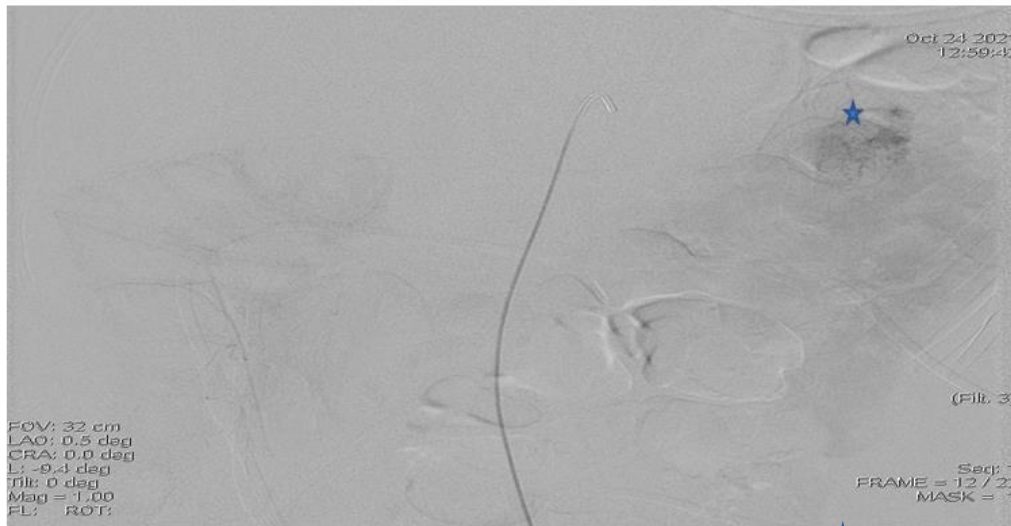


Figure 1: Arteriography image showing a jejunal blush ★

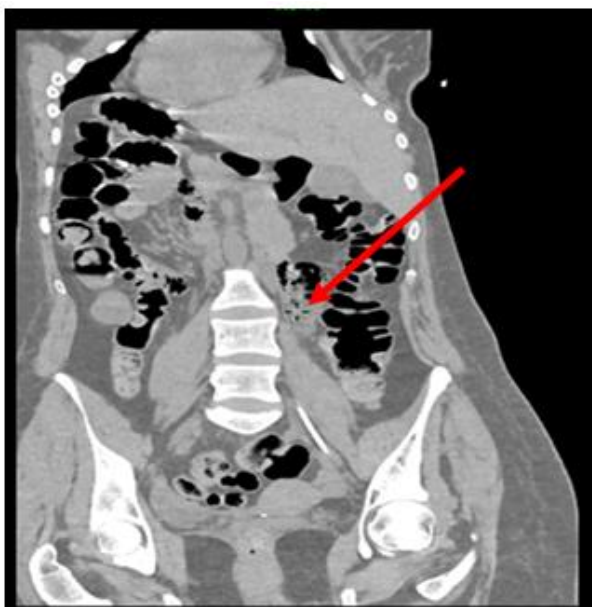

Figure 2: CT image showing a jejunal tumor process

The patient underwent an emergency operation and during the exploration a jejunal tumor was found 30 cm away from the Treitz angle; hence the realization of a bowel resection taking away the tumor with a latero-lateral mechanical bowel anastomosis (Figure 3).

The postoperative course was simple; the patient was discharged after one week of hospitalization; the anatomopathological study confirmed the diagnosis of jejunal Gist and patient did not received any adjuvant treatment.

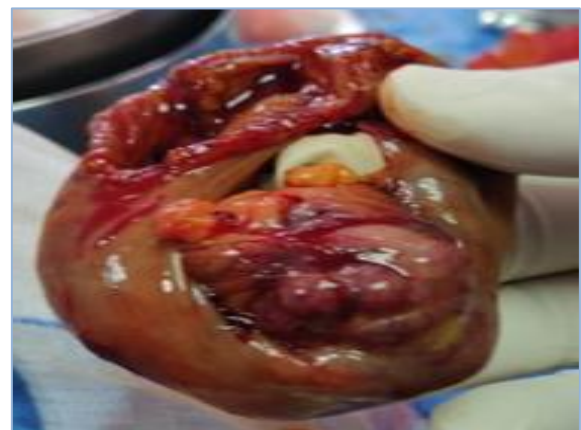

Figure 3: Operative Specimen of the jejunal tumor

Clinical Case N 2

A 26 year old patient with no notable clinical history consulted the emergency room for the management of heavy rectal bleeding. The clinical examination showed a patient with tachycardia at 120 bpm and a blood pressure at 100/50 mmhg.

A biological assessment was performed, showing an anemia of 6.9 g/dl normochromic with a platelet count of 226,000 e/mm³ and a PT of 88%.

An emergency fibroscopy was performed, but no active bleeding or obvious etiology was observed. Given the hemodynamic instability, a CT Angiography was performed, showing a mass at the jejunal loop, with tissue density, exophytic development, heterogeneously enhanced, with peripheral hyper vascularization, without clear extravasation of contrast at this level, measuring 40 x 32 mm in diameter (Figure 4).

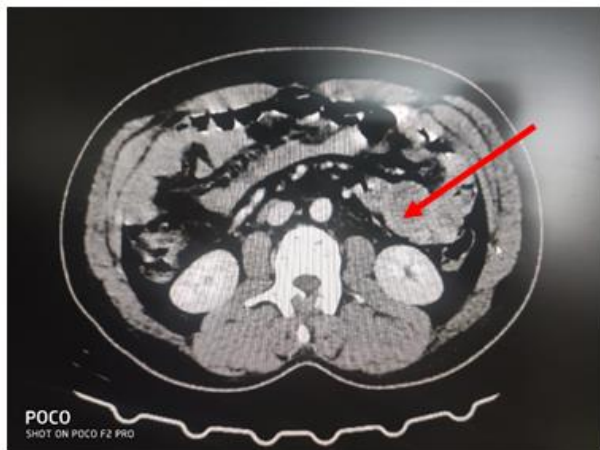


Figure 4: CT image of the hemorrhagic jejunal process "clinical case 2"

The decision was made to operate the patient urgently. During the exploration, a 4 cm large tumor was found at 50 cm from the treitz angle and a segment of the bowel was resected with manual end-to-end anastomosis.

Anatomopathological examination showed a jejunal GIST and the oncologist did not decide any adjuvant chemotherapy.

DISCUSSION

The majority of GISTs are located in the stomach (60-70%), while 20-30% are found in the small bowel and they are rarely located in the esophagus, colon, rectum, and retroperitoneum [5].

The site and size of the GIST influence the clinical presentation, management, and prognosis [6].

The mode of presentation of large GISTs is not specific; some patients may have no obvious symptoms with an incidental finding on routine physical examination or imaging. However, other patients may report abdominal pain or discomfort due to the mass effect on adjacent organs, or chronic anemia due to occult bleeding. In the later stage of tumor growth, a palpable abdominal mass; bowel obstruction or tumor rupture with hemorrhage may occur [7].

Among the many causes of GI bleeding, hemorrhagic jejunal GIST is one of the rarest etiologies and its diagnosis is challenging because of its inaccessibility by conventional upper and lower

endoscopy, which remains the first-line examination for GI bleeding [5].

CT is the most accredited tool to detect GIST, it presents as a well-circumscribed extraluminal mass with homogeneous enhancement in small tumors and heterogeneous enhancement due to a necrotic center in large tumors. The liver and peritoneum are specific sites for metastases if present [8].

In case of bleeding, upper and lower endoscopy is mandatory in the first line. If negative, CT Angiography is indicated in unstable patients; in stable patients, capsule endoscopy (CE) is the recommended first-line procedure for evaluation of the small bowel [6]. In case of failure of CE or in case of severe and persistent bleeding, double balloon enteroscopy will be a useful procedure for diagnostic and therapeutic purposes [9].

Angiography is considered once available as a key examination for the identification of the site of gastrointestinal bleeding. However, in cases of massive life-threatening gastrointestinal bleeding, emergency exploratory laparotomy represents a diagnostic and therapeutic procedure [1, 7].

A timely and correct diagnosis improves the management and prognosis of patients. The treatment of GIST is surgical excision, which should be an R0 resection with an intact pseudocapsule [5]. These tumors do not tend to metastasize to lymph nodes, making lymphadenectomy unnecessary [11].

However, despite complete excision with clear margins, GISTs tend to recur in 50% of cases [11].

The Armed Forces Institute of Pathology criteria and the modified NIH criteria allow patients to be classified according to their risk of recurrence in order to initiate adjuvant imatinib therapy [11].

Recent research shows that GI bleeds are due to tumor perforation through the mucosa and should therefore be treated in the same way as a perforated tumor at high risk of recurrence. Other studies suggest that GI bleeding may be an independent risk factor for recurrence and that these patients should receive adjuvant treatment with Imatinib [12].

CONCLUSION

In rare cases, proximal jejunal GIST can cause massive upper and lower gastrointestinal bleeding requiring urgent surgical intervention.

A multidisciplinary approach is mandatory for the correct management of this pathology. In our case the involvement of the surgical team in collaboration with radiology was the cornerstone of the management

of our patients and should be considered in all cases of massive GI bleeding.

It should also be noted that GIST with GI bleeding is more likely to recur and therefore GI bleeding can be used as a significant indicator to assess the prognosis of these patients in order to indicate adjuvant treatment with Imatinib.

REFERENCES

1. Zhou, L., Liao, Y., Wu, J., Yang, J., Zhang, H., Wang, X., & Sun, S. (2018). Small bowel gastrointestinal stromal tumor: a retrospective study of 32 cases at a single center and review of the literature. *Therapeutics and Clinical Risk Management*, 14, 1467-1781.
2. Mazur, M. T., & Clark, H. B. (1983). Gastric stromal tumors. Reappraisal of histogenesis. *The American journal of surgical pathology*, 7(6), 507-519.
3. Efremidou, E. I., Liratzopoulos, N., Papageorgiou, M. S., Romanidis, K., Manolas, K. J., & Minopoulos, G. J. (2006). Perforated GIST of the small intestine as a rare cause of acute abdomen: surgical treatment and adjuvant therapy. Case report. *Journal of Gastrointestinal and Liver Diseases*, 15(3), 297-299.
4. Miettinen, M., & Lasota, J. (2011). Histopathology of gastrointestinal stromal tumor. *Journal of surgical oncology*, 104(8), 865-873.
5. Mahmoud, S., Salman, H., & Salami, M. (2020). A rare case report of locally recurrent hemorrhagic duodenal gastrointestinal stromal tumor: therapeutic challenges and review of prognostic indicators for recurrence. *Journal of Surgical Case Reports*, 2020(1), rjz365.
6. Mandalà, S., Lupo, M., Guccione, M., La Barbera, C., Iadicola, D., & Mirabella, A. (2021). Small bowel gastrointestinal stromal tumor presenting with gastrointestinal bleeding in patient with type 1 Neurofibromatosis: Management and laparoscopic treatment. Case report and review of the literature. *International Journal of Surgery Case Reports*, 79, 84-90.
7. Saad, M. K., El Hajj, I., & Saikaly, E. (2020). Jejunal gastrointestinal stromal tumor (GIST): a case report presenting as life threatening emergency. *Gastrointest Stromal Tumor*, 3(0). Disponible sur: <https://gist.amegroups.com/article/view/46162>
8. Abdel-Monem, S., Enaba, M. M., Hassan, T. A., & Attia, M. A. (2011). Multislice CT imaging of gastrointestinal stromal tumors (GISTs). *The Egyptian Journal of Radiology and Nuclear Medicine*, 42(1), 1-7.
9. Gerson, L. B., Fidler, J. L., Cave, D. R., & Leighton, J. A. (2015). ACG clinical guideline: diagnosis and management of small bowel bleeding. *Official journal of the American College of Gastroenterology/ACG*, 110(9), 1265-1287.
10. Dualim, D. M., Loo, G. H., Rajan, R., & Mahmood, N. R. K. N. (2019). Jejunal GIST: hunting down an unusual cause of gastrointestinal bleed using double balloon enteroscopy. A case report. *International journal of surgery case reports*, 60, 303-306.
11. Balachandran, V. P., & DeMatteo, R. P. (2014). Gastrointestinal stromal tumors: who should get imatinib and for how long?. *Advances in surgery*, 48(1), 165-183.
12. Liu, Q., Li, Y., Dong, M., Kong, F., & Dong, Q. (2017). Gastrointestinal bleeding is an independent risk factor for poor prognosis in GIST patients. *BioMed research international*, 2017: e7152406.