

Cardiac MRI Imaging in the Diagnosis of Acute Myocarditis in a Young Athlete

Benmessaoud F. Z^{1*}, Nawal Doghmi¹, Benacer Med¹, Youssef Fakir², Oukerraj Latifa¹, Mohamed Cherti¹

¹MD, Cardiology B Department of CHU Ibn Sina Rabat, Morocco

²MD, Radiology department of Agdal clinic Rabat, Morocco

DOI: [10.36348/sjm.2021.v06i10.005](https://doi.org/10.36348/sjm.2021.v06i10.005)

| Received: 25.08.2021 | Accepted: 30.09.2021 | Published: 16.10.2021

*Corresponding Author: Benmessaoud F. Z

Abstract

Acute myocarditis is inflammation of the myocardium most often following a viral infection. Its diagnosis is one of the most difficult to make with certainty in cardiology, due to the lack of specificity of the clinical presentation, ECG and ultrasound changes, and the restrictive use of myocardial biopsy (BM). For these reasons, we report the case of a 22-year-old athlete who presented with severe chest pain. Cardiac MRI allows direct characterization of myocardial damage; different diagnostic sequences make it possible to locate areas of inflammation, edema, and necrosis, and the distribution of lesions in the muscle makes it possible to distinguish between ischemic and inflammatory damage.

Keywords: Myocarditis- Athlete- MRI.

Copyright © 2021 The Author(s): This is an open-access article distributed under the terms of the Creative Commons Attribution **4.0 International License (CC BY-NC 4.0)** which permits unrestricted use, distribution, and reproduction in any medium for non-commercial use provided the original author and source are credited.

INTRODUCTION

Inflammatory cardiomyopathy, characterized by inflammatory cell infiltration into the myocardium with a high risk of deteriorating cardiac function and has a heterogeneous aetiology [1]. Although endomyocardial biopsy (EMB) is considered the gold standard for diagnosis of myocarditis, this due to its complications and low sensitivity is not performed routinely and remains limited to certain indications [2]. The standard diagnostic examination is cardiac magnetic resonance imaging (cMRI), based on Lake Louise diagnostic criteria, based on the identification of edema and capillary hyperemia, necrosis, or myocardial fibrosis [3].

Case

A 22-year-old athlete without cardiovascular risk factors or previous history of cardiovascular disease presented to the emergency department in our institution for chest pain occurring at rest and persisting for 24 hours. The patient could not recall any recent

acute infection or symptoms such as coughing, sore throat, or diarrhoea. The physical examination revealed blood pressure of 130/70 mmHg, heart rate of 75 b.p.m., oxygen saturation of 98% while breathing ambient air. The electrocardiogram showed diffuse ST elevation without reciprocal changes (Figure 1). Transthoracic echocardiography showed mild diffuse hypokinesia with left ventricular ejection fraction (LVEF) at 52%, preserved cardiac output, normal right ventricular function, no significant valvular disease, and no pericardial effusion. Blood tests revealed an elevated cardiac troponin. The diagnosis of myocarditis was suspected. Cardiac magnetic resonance (CMR) imaging was performed on the day of admission and showed mild left ventricular dysfunction with LVEF of 53% and normal right ventricular function. Tissue characterization based on T2-weighted and late gadolinium enhancement sequences revealed interstitial edema and sub-epicardial anterolateral and antero-septal wall delayed gadolinium enhancement. The first-pass perfusion was normal (Figures 2 & 3).

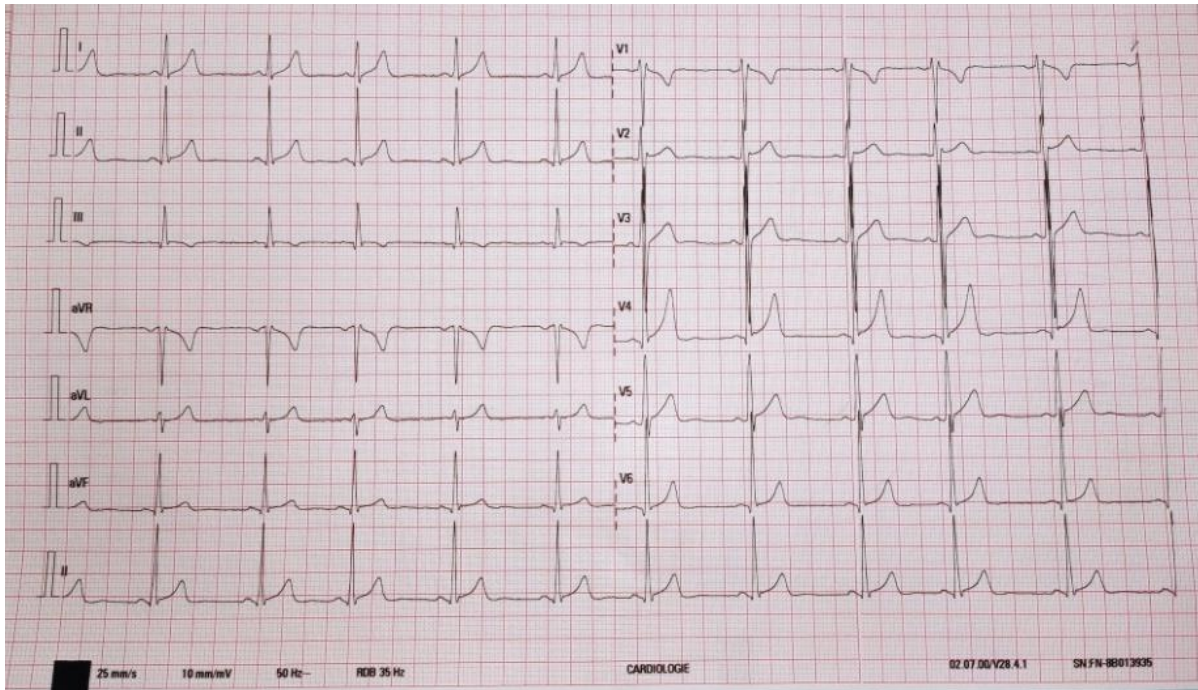


Figure 1: The electrocardiogram showed diffuse ST elevation without reciprocal changes

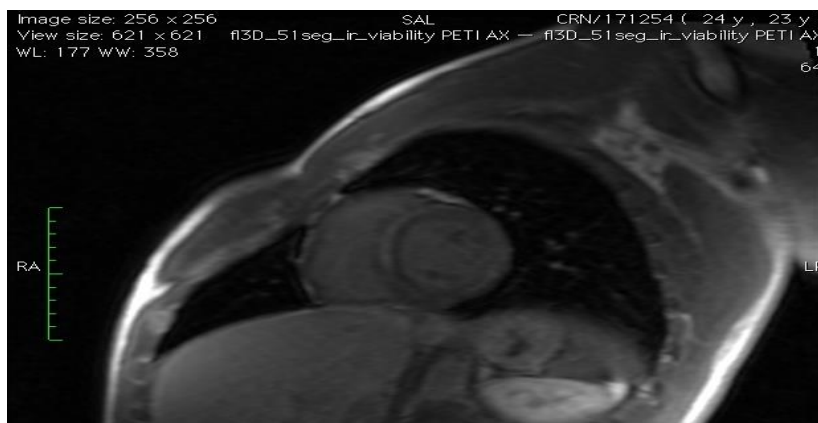


Figure 2: Short-axis view showed diffuse myocardial signal hyperintensity involving the anterolateral and septal walls of the left ventricle, suggesting interstitial oedema

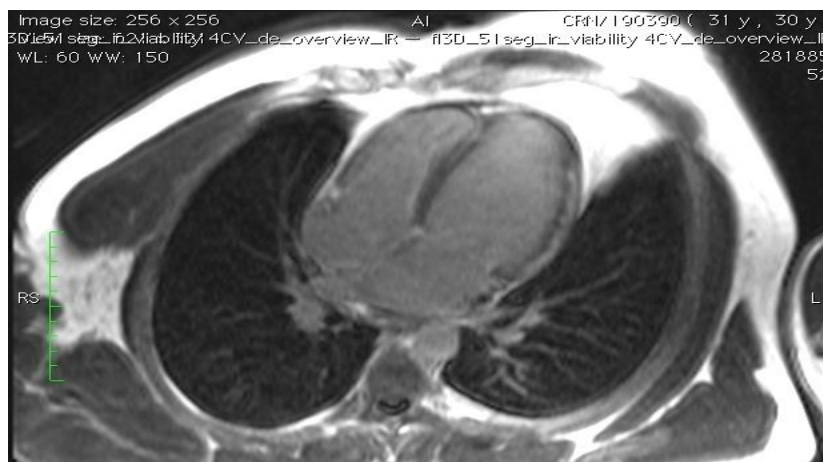


Figure 3: Apical view showed diffuse myocardial signal hyperintensity involving the anterolateral and septal walls of the left ventricle, suggesting interstitial oedema

DISCUSSION

In the different data, the clinical and paraclinical presentation of myocarditis is polymorphic in both athletes and non-athletes (even in athletes) [4]. Unlike other cardiomyopathies, there is no particularity in the positive diagnosis of myocarditis in athletes compared to sedentary subjects [4]. The clinical presentation described in the different series of myocarditis in athletes varied from the asymptomatic form to sudden death, including congestive heart failure, cardiogenic shock, or simulate myocardial infarction [4].

Cardiac MRI has been ordered to look for signs of myocarditis that are Myocardial hyperemia, demonstrated by early global enhancement of the myocardium with gadolinium during a T1-weighted sequence; Regional or global myocardial edema, evidenced by hyperintensity in T2-weighted sequence and Myocardial necrosis or fibrosis, most often multifocal epicardial localization (as opposed to subendocardial scars of ischemic origin), demonstrated by late enhancement with gadolinium in T1-weighted sequence [3]. These 3 elements were found in our patient leading to the conclusion of acute myocarditis of the anterolateral and antero-septal walls.

In most cases found in literature, the diagnosis of myocarditis is made post mortem following a cardiac arrest during exercise. A clinical case almost similar to our case was reported by Nishant, it was a 36-year-old cyclist who presented with acute chest pain with an ST-segment elevation requiring an emergency coronary angiography which was normal. The diagnosis of myocarditis was confirmed by sub-epicardial lateral and wall delayed gadolinium enhancement on the cardiac MRI [5].

Six months of cessation of sporting activity was proposed to our athlete. Resumption of sports activity will only be considered after the disappearance of the symptoms and the normalization of abnormalities in the biological assessment, the ECG, the ETT, Holter ECG, and the stress test (IIa, C) [4].

A follow-up MRI is also planned to look for the persistence of late enhancement which is evidence of an injury scare in the myocardium which may be the source of Ventricular tachycardia. Its presence should not prevent the resumption of sporting activity. In addition, it imposes an annual clinical follow-up [4].

Several studies (including a series of 670 patients and another of 374 athletic or non-athletic patients) have shown that after myocarditis, the presence of myocardial fibrosis is an independent poor prognostic factor associated with an increased risk of the occurrence of elements. Major cardiovascular disease and death, even when LVEF is normal. In both series, the risk was greater when the late enhancement

was localized at the level of the interventricular septum [6, 7].

CONCLUSION

We report here the case of a young athlete presenting with isolated acute myocarditis. Unlike other cardiomyopathies, there is no particularity in the positive diagnosis of myocarditis in athletes compared to sedentary subjects.

Currently, the non-invasive gold-standard method for the diagnosis of myocarditis is cardiac MRI [3] based on Lake Louise diagnostic criteria, based on the identification of edema and capillary hyperemia, necrosis, or myocardial fibrosis.

Conflict of Interest: The Authors declare that there is no conflict of interest.

REFERENCES

1. Caforio, A. L., Pankuweit, S., Arbustini, E., Basso, C., Gimeno-Blanes, J., Felix, S. B., ... & Elliott, P. M. (2013). Current state of knowledge on aetiology, diagnosis, management, and therapy of myocarditis: a position statement of the European Society of Cardiology Working Group on Myocardial and Pericardial Diseases. *European heart journal*, 34(33), 2636-2648.
2. Cooper, L. T., Baughman, K. L., Feldman, A. M., Frustaci, A., Jessup, M., Kuhl, U., ... & Virmani, R. (2007). The role of endomyocardial biopsy in the management of cardiovascular disease: a scientific statement from the American Heart Association, the American College of Cardiology, and the European Society of Cardiology. Endorsed by the Heart Failure Society of America and the Heart Failure Association of the European Society of Cardiology. *J Am Coll Cardiol*, 50(19), 1914-1931.
3. Ferreira, V. M., Schulz-Menger, J., Holmvang, G., Kramer, C. M., Carbone, I., Sechtem, U., ... & Friedrich, M. G. (2018). Cardiovascular magnetic resonance in nonischemic myocardial inflammation: expert recommendations. *Journal of the American College of Cardiology*, 72(24), 3158-3176.
4. Pelliccia, A., Solberg, E. E., Papadakis, M., Adami, P. E., Biffi, A., Caselli, S., ... & Sharma, S. (2019). Recommendations for participation in competitive and leisure time sport in athletes with cardiomyopathies, myocarditis, and pericarditis: position statement of the Sport Cardiology Section of the European Association of Preventive Cardiology (EAPC). *European heart journal*, 40(1), 19-33.
5. Nishant, S., & Dermot, M. J. (2018) Myocarditis in the Athlete. *Am Coll cardiol*.
6. Gräni, C., Eichhorn, C., Bière, L., Murthy, V. L., Agarwal, V., Kaneko, K., ... & Kwong, R. Y. (2017). Prognostic value of cardiac magnetic

resonance tissue characterization in risk stratifying patients with suspected myocarditis. *Journal of the American College of Cardiology*, 70(16), 1964-1976.

7. Aquaro, G. D., Perfetti, M., Camastra, G., Monti, L., Dellegrottaglie, S., Moro, C., ... & Cardiac

Magnetic Resonance Working Group of the Italian Society of Cardiology. (2017). Cardiac MR with late gadolinium enhancement in acute myocarditis with preserved systolic function: ITAMY study. *Journal of the American College of Cardiology*, 70(16), 1977-1987.