

Spontaneous Hepatic Rupture Induced by Behcet's Disease: A Case Report

Aboulfeth El Mehdi^{1*}, Anajar Mohamed¹, Bouzroud Mohamed¹, El Kassimi Ilyas², Sekkach Youssef², Ait Ider Badr¹, Bouchentouf sidi Mohamed¹, El Hajouji Abderrahman¹, Zentar Aziz¹

¹Department of surgery, military hospital of Rabat, Morocco

²Department of medicine, military hospital of Rabat, Morocco

DOI: [10.36348/sjm.2019.v04i07.009](https://doi.org/10.36348/sjm.2019.v04i07.009)

| Received: 21.07.2019 | Accepted: 28.07.2019 | Published: 30.07.2019

*Corresponding author: Aboulfeth El Mehdi

Abstract

Non traumatic liver rupture is an extremely rare condition; it most often complicates HELLP syndrome and rarely some liver diseases. We are reporting a case of 26-year-old man followed for behcet's disease, presented to the emergency hemodynamically instable on a large hemoperitoneum due to a spontaneous liver rupture. We believe that intrahepatic hematoma was caused by a rupture of a segmental right liver artery aneurysm and then spontaneous rupture of the intrahepatic hematoma occurred leading to liver rupture. The surgical management consisted on perihepatic packing and two months later a medical management of sub infected liquefied residual liver hematoma.

Keywords: Spontaneous liver rupture; Behcet's disease, hemoperitoneum, perihepatic packing.

Copyright © 2019: This is an open-access article distributed under the terms of the Creative Commons Attribution license which permits unrestricted use, distribution, and reproduction in any medium for non-commercial use (Non-Commercial, or CC-BY-NC) provided the original author and source are credited.

INTRODUCTION

Non traumatic liver rupture is an extremely rare condition and constitutes a real diagnostic and therapeutic challenge in male gender. It most often complicates HELLP syndrome or preeclampsia in pregnant women and rarely some liver diseases and exceedingly rare occurs among systemic diseases [1]. Only few cases have been reported in the literature.

Behcet's disease is a multisystemic disease characterized by vascular involvement that affects as well as the venous and the arterial compartment and vessels of different size.

We are reporting a case of an hemoperitoneum due to a spontaneous liver rupture, in a young man followed for Behcet's disease, that was managed surgically and discussing the etiological theories of this uncommon condition.

CASE REPORT

A 26-year-old man, taking a daily dose of 10 mg of prednisone for Behcet's Disease (BD) and was treated three year ago for a deep vein thrombosis of the right lower limb, presented to the emergency department for acute right upper abdominal pain for one day with no history of trauma, which was aggravated in

two hours, accompanied by dizziness and sweating. He was immediately admitted to intensive care as the patient's heart rate was 102 per minute and blood pressure 80/68 mmHg. Resuscitation by fluid and norepinephrine was started immediately.

On physical examination, no pallor or jaundice was noted. Total abdominal tenderness, mild rebound pain, liver and kidney area percussion pain (+), shifting dullness (+), and weak bowel sounds were noted.

Laboratory investigations showed hemoglobin of 7. g/dl, white cell count: 780 5/ µl, platelet count 120000/ µl and INR 1.01. Liver function tests showed normal bilirubin, albumin, and enzymes.

Focused abdominal sonogram for trauma (FAST) showed free fluid with hyper echoic area in the abdomen. Hemoperitoneum was suspected and contrast-enhanced CT revealed a normal sized liver with a large sub capsular hematoma and hemoperitoneum. Limited hypodense range straddling the V, VI, VIII segments of the liver and also showed an extravasation of the contrast product in contact with a segmental right hepatic artery. There were no cysts or hemangiomas of the liver (Fig 1).

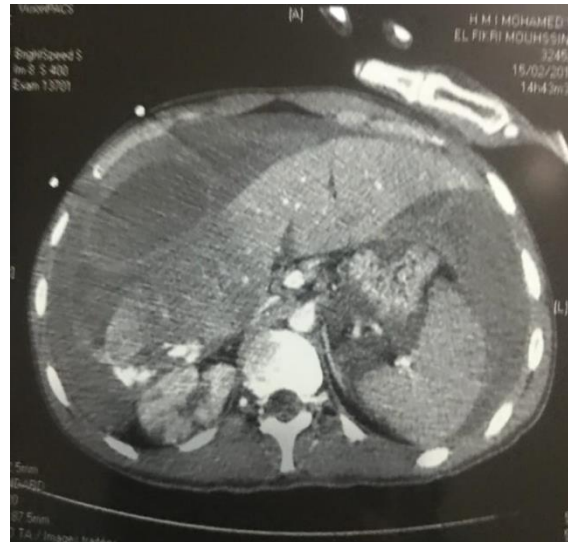


Fig-1: CT scan revealed a large sub capsular hematoma and hemoperitoneum and showed an extravasation of the contrast

The patient was immediately sent to the operating room. Upon a midline incision, approximately 2 L of frank hemoperitoneum was evacuated. Exploration identified a deep laceration of

segments VI and VII at the bottom of a subcapsular hematoma of the liver as the origin of the active bleeding (Fig 2). There were no sign of liver neoplasm and other viscera and bowel were free.

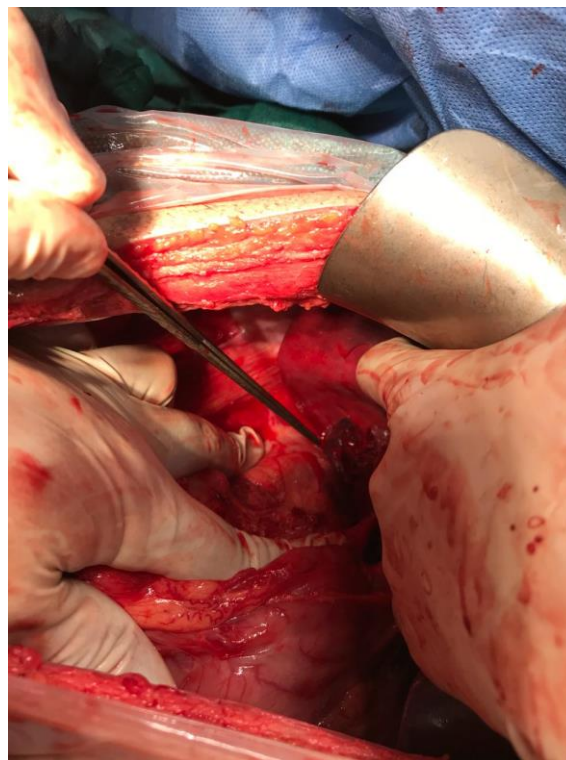


Fig-2: Per operative image showing a deep laceration of segments VI and VII of the liver on active bleeding

According to the principle of damage control, we carried out conservative treatment, and though ligating the bleeding artery and suturing the ruptured parenchyma were unsatisfying, we performed Perihepatic packing.

The patient was monitored in the Intensive Care Unit and liver packing was removed 48 hours after (Fig 3). The immediate postoperative courses were satisfying, and the patient was discharged after two weeks of hospitalization with no disability.

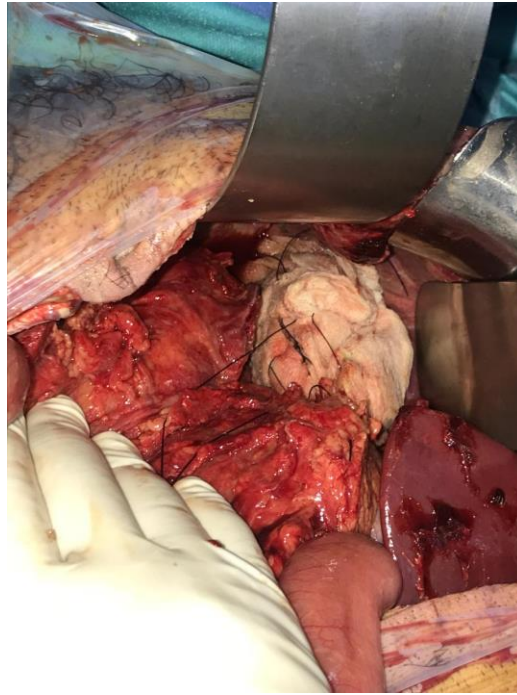

Fig-3: Per operative image showing liver packing removal

Two months after surgery; the patient presented an upper right quadrant pain with fever. a CT scan showed a sub infected liquefied hematoma of the dorsal surface of segment VI and small segmental aneurysms of segments III and VII (Fig 4), treatment

consisted on percutaneous drainage and Intravenous antibiotics. Apyrexia was obtained within 3 days and a per os antibiotherapy was therefore started for four weeks.

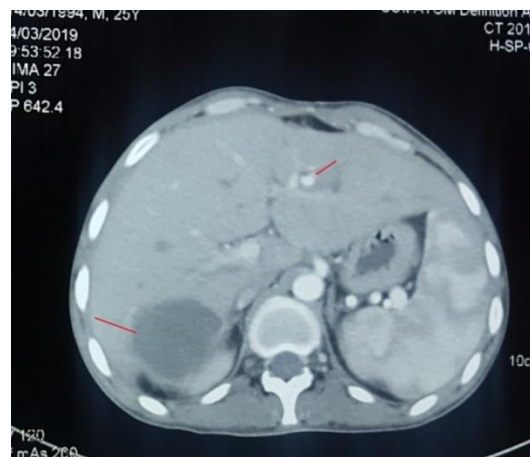


Fig- 4: CT scan showed a sub infected liquefied hematoma of the dorsal surface of segment VI and small's segmental aneurysms of segments III and VII

DISCUSSION

In 1844, Abercrombie gave the first description of spontaneous liver hematoma and its rupture in pregnant women. It occurs in about 1-2% of all preeclampsia cases and HELLP syndrome [1, 2]. In male gender; the etiology of spontaneous liver rupture, in the absence of trauma and lack of coagulation, is widely dominated by tumors, among which hepatocellular carcinomas (86%) and hepatic adenomas (6%) are extensively found [3]. Other neoplasms such as hemangiomas, gastrointestinal and lung carcinomas metastasis, lymphoma and focal nodular hyperplasia

were mentioned in the literature [4]. Non neoplastic causes include amyloidosis, rheumatoid arthritis, and systemic lupus [5].

The clinical presentation is often non-specific, Careful history findings, physical examination with necessary laboratory tests and imaging can provide enough clues for an easy diagnosis of liver rupture. [4].

A typical patient usually presents severe upper abdominal pain, abdominal distension, anorexia and vomiting. Rupture usually occurs during physical activity or after a slight injury. Facial pallor, cold sweat,

pulse > 100 times/minute, systolic pressure < 90 mmHg, rebound tenderness and muscular tension over upper abdomen, suggest that the disease would be quite serious [4].

Radiological adjuncts such as ultrasound, CT scan, or MRI are useful for the diagnosis. The most common evaluative imaging in emergency states is the CT scan, it may be useful in the diagnosis and identifying an active bleeding [6].

However, over half of patients undergoing an acute CT scan will have evidence of intrahepatic hematoma with less than half having evidence of hemoperitoneum. In addition, up to 20% of patients may be hemodynamically unstable on arrival to hospital and proceed straight to theatre where the diagnosis is made intra-operatively.

Magnetic resonance imaging, currently under evaluation, is likely to have a place in this type of pathology, especially since it is not radiating [7]. It is of no interest in an emergency context, but may be useful in the secondary detection of possible causal lesions. Its realization must not delay the therapeutic action [6,8].

The present case satisfied the international criteria for Behcet's disease [9] with vascular involvement. BD is a chronic, inflammatory vascular disease with no pathognomonic test [9]. There is a male predominance at a ratio of nine to one for vascular involvement. Both venous and arterial compartment can be affected. Vascular involvement is the major life-threatening manifestation. Involvement of visceral vessels is rare. Aneurysms in Behcet's disease appear at a younger age, approximately seven years after the diagnosis and tend to be more saccular (Figure 1 and 2) compared to the fusiform degenerative aneurysms [10]. Aneurysms rarely occur in the visceral arteries [11].

Through preoperative and per operative exploration, we excluded a neoplastic origin of the hemorrhage, and we believe that intrahepatic hematoma was caused by a rupture of a segmental right liver artery aneurysm and then spontaneous rupture of the intrahepatic hematoma occurred leading to liver rupture.

Early diagnosis of BD in young males with aneurysms is critical to avoid any ruptured aneurysms. [12] Early diagnosis may be based on radiographic imaging such as ultrasound angiography, CT, and magnetic resonance angiography. CECT has become the procedure of choice in evaluating patients with aneurysm. Selective angiography has proven to be useful for both the diagnosis and treatment of intestinal bleeding [13].

Because this is a rare condition, no single institution has accumulated enough experience to be

able to make conclusive recommendations about treatment [14]. Hemodynamically stable patients with intact liver capsule and contained hematoma should be followed up conservatively by means of intensive medical support and a hemoglobin monitoring.

Patients with unstable hemodynamic condition should go for urgent laparotomy, where peri hepatic packing, artery ligating or liver resection can be done. In rare cases, total hepatectomy followed by liver transplantation may be the only option available for severe uncontrolled hemorrhage [15]. Stable patients who are diagnosed to have an aneurysm, interventional radiological procedures like angiographic coiling or embolization pre operatively or during the surgery is an option [16].

Consent

Written informed consent was obtained from the patient for publication of this case report and any accompanying images. A copy of the written consent is available for review by the Editor of this journal.

Conflict of interest

The authors declare that there is no conflict of interests regarding the publication of this paper.

Authors' contribution

All authors participated in the care of the patient and the writing of the manuscript. All authors have read and approved the final version of the manuscript.

CONCLUSION

Spontaneous hepatic hemorrhage is a rare condition that results from a breach in the hepatic parenchyma that occurs without an external cause. In vasculo behcet, the increased fragility of artery walls and aneurysm is an adequate condition for bleeding with even minor liver trauma. The immediate care, in the context of an emergency, coincides with that of hepatic trauma.

REFERENCES

1. Klein, K., & Shapiro, A. M. (2011). Spontaneous hepatic rupture with intraperitoneal hemorrhage without underlying etiology: a report of two cases. *ISRN surgery*, 2011.
2. Wicke, C., Pereira, P. L., Neeser, E., Flesch, I., Rodegerdts, E. A., & Becker, H. D. (2004). Subcapsular liver hematoma in HELLP syndrome: evaluation of diagnostic and therapeutic options—a unicenter study. *American journal of obstetrics and gynecology*, 190(1), 106-112.
3. Polat, K. Y., Akcay, M. N., Aydinli, B., Erdogan, F., Kantarci, M., Öztürk, G., & Peker, K. (2005). Spontaneous rupture of hepatocellular carcinoma: a case report and review of literature. *International Journal of Clinical Practice*, 59, 103-105.

4. Chen, Z. Y., Qi, Q. H., & Dong, Z. L. (2002). Etiology and management of hemorrhage in spontaneous liver rupture: a report of 70 cases. *World journal of gastroenterology*, 8(6), 1063.
5. Loss, M., Ng, W. S., Karim, R. Z., Strasser, S. I., Koorey, D. J., Gallagher, P. J., ... & McCaughan, G. W. (2006). Hereditary lysozyme amyloidosis: spontaneous hepatic rupture (15 years apart) in mother and daughter. Role of emergency liver transplantation. *Liver transplantation*, 12(7), 1152-1155.
6. Chae, E. J., Do, K. H., Seo, J. B., Park, S. H., Kang, J. W., Jang, Y. M., ... & Kim, A. Y. (2008). Radiologic and clinical findings of Behçet disease: comprehensive review of multisystemic involvement. *Radiographics*, 28(5), e31.
7. Srinivasa S, Lee WG, Aldameh A, Koea JB. Spontaneous hepatic haemorrhage: a review of pathogenesis, aetiology and treatment. *Hpb*. 2015 Oct 1;17(10):872-80.
8. Lahmidani, S., Abssi, M., Ounani, M., Charrab, M., Alami, F., Amraoui, M., ... & Chkoff, R. (2010). Hématome sous-capsulaire du foie spontané idiopathique: à propos d'un cas. *Journal africain d'hépatogastroentérologie*, 4(1), 54-56.
9. International Team for the Revision of the International Criteria for Behçet's Disease (ITR-ICBD), Davatchi, F., Assaad-Khalil, S., Calamia, K. T., Crook, J. E., Sadeghi-Abdollahi, B., ... & Al-Dalaan, A. (2014). The International Criteria for Behçet's Disease (ICBD): a collaborative study of 27 countries on the sensitivity and specificity of the new criteria. *Journal of the European Academy of Dermatology and Venereology*, 28(3), 338-347.
10. Tuzun, H., Seyahi, E., Arslan, C., Hamuryudan, V., Besirli, K., & Yazici, H. (2012). Management and prognosis of nonpulmonary large arterial disease in patients with Behçet disease. *Journal of vascular surgery*, 55(1), 157-163.
11. Kuzu, M. A., Özaslan, C., Köksoy, C., Gürlü, A., & Tüzüner, A. (1994). Vascular involvement in Behçet's disease: 8-Year audit. *World journal of surgery*, 18(6), 948-953.
12. Merashli, M., El Eid, R., & Uthman, I. (2018). A review of current management of vasculo-Behçet's. *Current opinion in rheumatology*, 30(1), 50-56.
13. Wu, X. Y., Wei, J. P., Zhao, X. Y., Wang, Y., Wu, H. H., Shi, T., ... & Liu, G. (2015). Spontaneous intra-abdominal hemorrhage due to rupture of jejunal artery aneurysm in Behçet disease: case report and literature review. *Medicine*, 94(45).
14. Mascarenhas, R., Mathias, J., Varadarajan, R., Geoghegan, J., & Traynor, O. (2002). Spontaneous hepatic rupture: a report of five cases. *HPB*, 4(4), 167-170.
15. Hunter, S. K., Martin, M., Benda, J. A., & Zlatnik, F. J. (1995). Liver transplant after massive spontaneous hepatic rupture in pregnancy complicated by preeclampsia. *Obstetrics & Gynecology*, 85(5), 819-822.
16. Smith, J. L., Moise, J. K., & Carpenter, J. R. (1991). Spontaneous rupture of liver during pregnancy: current therapy. *Obstetrics and gynecology*, 77(2), 171-175.