

Nasolabial Flap in OPVL of RMT Including GB Sulcus - A Case Report

Dr. Shaan-e-Kareemi^{1*}, Dr. Mohammed Faisal², Dr. B. Vinod Kumar³, Dr. Kaushal Charan Pahari⁴, Dr. B. Harshitha⁵, Dr. Rahul Vinay Chandra Tiwari⁶

¹Senior Resident Surgeon & PG Student, Department of OMFS, Al Ameen Medical/Dental College & Hospital, Bijapur, Karnataka India

²Final year PG, Dept of OMFS, KMCT Dental College, Manassery, Kerala

³MDS, Assistant Professor, Department of Oral and Maxillofacial Surgery, Sri Sai College of Dental Surgery, Vikarabad, India

⁴PG Student, OMFS, Surendra Dental College & RI, Sriganaganagar, Rajasthan, India

⁵Senior Lecturer, Department of Periodontics, Sri Sai College of dental surgery, Vikarabad India

⁶FOGS, MDS, Assistant Professor, Department of Oral and Maxillofacial Surgery, Sri Sai College of Dental Surgery, Vikarabad, India

*Corresponding author: Dr. Shaan-e-Kareemi

| Received: 01.03.2019 | Accepted: 05.03.2019 | Published: 30.03.2019

DOI: [10.36348/sjm.2019.v04i03.004](https://doi.org/10.36348/sjm.2019.v04i03.004)

Abstract

Proliferative verrucous leukoplakia (PVL) is a rare form of oral leukoplakia, which was first described in 1985 by Hansen *et al.* Since then, various published case series have presented PVL as a disease with aggressive biological behavior due to its high probability of recurrence and a high rate of malignant transformation, usually higher than 70%. PVL is a long-term progressive condition, which is observed more frequently in elderly women, over 60 years at the time of diagnosis. We here by present a case of oral proliferative verrucous leukoplakia of retromolar triangle including gingivobuccal sulcus where nasolabial flap was used for reconstruction of the defect.

Keywords: Carcinoma, leukoplakia, malignant transformation, proliferative verrucous leukoplakia.

Copyright © 2019: This is an open-access article distributed under the terms of the Creative Commons Attribution license which permits unrestricted use, distribution, and reproduction in any medium for non-commercial use (Non-Commercial, or CC-BY-NC) provided the original author and source are credited.

INTRODUCTION

The buccal mucosa and tongue are the most frequently involved sites. It develops initially as a white plaque of hyperkeratosis that eventually becomes a multifocal disease with confluent, exophytic and proliferative features with a progressive deterioration of the lesions, making it more and more difficult to control. Tobacco use does not seem to have a significant influence on the appearance or progression of PVL and may occur both in smokers and nonsmokers. Prognosis is poor for this seemingly harmless-appearing white lesion of the oral mucosa. At present, the etiology of PVL remains unclear as well as its management and diagnosis, which is still retrospective, late and poorly defined, lacking consensus criteria. Oral cavity cancer worldwide comprises in between the sixth to the eighth most common malignant lesion and it encompasses around 30% of all head and neck cancers [1-3,4]. Retromolar trigon (RMT) is the buccal region near the lower third molar tooth and in the dry mandibles is a triangular area bounded by temporal crest on the medial side, anterior border of ramus on the lateral side, and base posterior to the socket for the third molar (Fig. 1)[5]. That has affected in 15% of all oral cancers [6-8]. Tumors in the

mucosa of the RMT progress insidiously and blowout rapidly into surrounding structures. Surgery can put significant structures at risk such as the lingual nerve, submandibular duct, and palatoglossus [9]. This could disturb sensation, speech, swallowing, tongue movements, and pose instant concerns for specialists operating in this area, RMT cancer with 1 cm safety borders all round fallouts in large oral defect. Slight defects can be left to heal by secondary intention or are mended by primary closure, buccal advancement flap, palatal pedicled flap, split-thickness skin grafting or tongue flap [10, 11]. Reconstruction of larger retromolar defects using pedicled buccal pad of fat flap is frequently insufficient and may be oncologically unsafe when the tumor is abutting or infiltrating the buccal pad of fat [12-16]. Pedicled and free myocutaneous flaps albeit safe and robust, are not suitable options due to additional, unnecessary muscle bulk. The pectoralis major myocutaneous flap carries about 15% flap related complications with the disadvantages of being bulky, the need of a second stage for pedicle division, unacceptable donor site scar in females [18,19]. Thus, RMT defects too wide to be covered with local flaps and are best served if local reconstruction is to be considered.

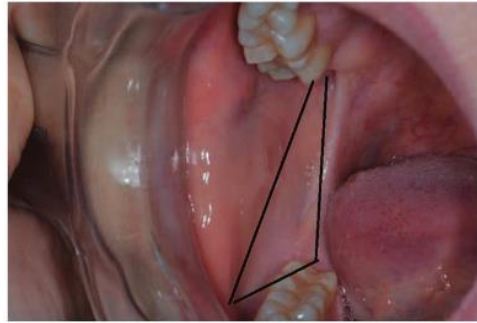


Fig-1: Retromolar Triangle Area

CASE REPORT

A 60-year female came to our dept. with the chief complaint of burning sensation and reduced mouth opening with respect to a diffused red and white lesion in the lower left side of the mouth. On clinical examination, a diffused white lesion with areas of pink dispersion in between was present on the left side of retromolar trigone of size 4×3 cm extending anteriorly to involve gingiva of the third molar, extending superiorly to maxillary tuberosity with reduced mouth opening. Lymph nodes were non palpable, and non-tender. The incisional biopsy was made and the report

for the same confirmed dysplastic changes on one side and carcinoma in situ on the other side confirming for oral proliferative verrucous leukoplakia as per the criteria given by Cerero-Lapiedra *et al.*[20]. On the basis of preoperative work-up, we performed wide local excision with safe margins along with reconstruction of the defect by nasolabial flap by tunneling it, at a later stage the donor flap was resected once it was well taken up at the local site. The defect reconstruction was utmost important to prevent the morbidity of the local site (fig 2).

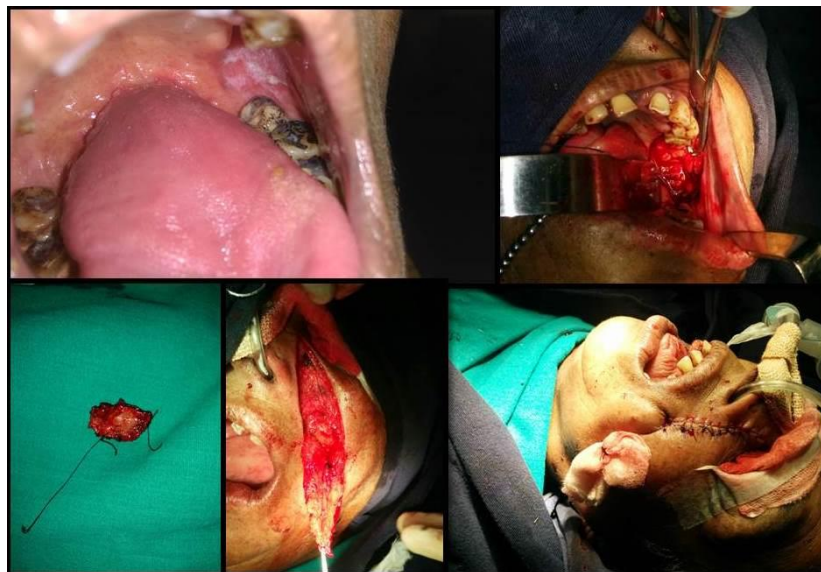

Fig-2: Clinical and Operative Pictures including excision and reconstruction

DISCUSSION

The mucosal surface of the retromolar trigone becomes continuous with the buccal mucosa laterally and the soft palate medially. The patient generally presents with symptoms of pain and trismus. In severe cases where one can suspect the involvement of the nerve, patient may present with paresthesia along the distribution of inferior alveolar nerve [21]. OPVL is known for its violent [22] pathology, suggestive of multifocal involvement, high malignant transformation rates (60-100%), recurrent (87-100%) and high mortality rates (30-50%) [19]. the gingiva and palate represented the areas with the highest frequency of

these multiple malignant tumors [20]. Given the high tendency for (OSCCs) to appear in these patients, they should be checked for life at least once every 6 months [24].

CONCLUSION

OPVL is a rare entity, but decidedly destructive form of Oral Leukoplakia, which requires attention and the clinician, must be aware of the same. Literature suggests earliest possible intervention to diagnose this special entity and total excision of this lesion and reconstruction if required. The objective of reporting this case was to report a case with typical

clinical and histologic features of OPVL so as to brief the oral physicians. The attention should be taken to follow-up these cases for a long time even after surgical management as these entities have sophisticatedly higher recurrence rate and are well documented to undergo malignant transformation.

REFERENCES

- Jemal, A.R., Siegel, E., Ward, T., Murray, J.Q., Xu, C. (2006) Cancer statistics. *CA Cancer J Clin.* 56: 106-130.
- McGregor, I. A., & McGregor, F. M. (1986). *Cancer of the face and mouth: pathology and management for surgeons.* Churchill Livingstone.
- Mignogna, M. D., Fedele, S., & Russo, L. L. (2004). The World Cancer Report and the burden of oral cancer. *European journal of cancer prevention*, 13(2), 139-142.
- Parkin, D. M., Bray, F., Ferlay, J., & Pisani, P. (2005). Global cancer statistics, 2002. *CA: a cancer journal for clinicians*, 55(2), 74-108.
- Mehanna, H., Paleri, V., West, C. M. L., & Nutting, C. (2011). Head and neck cancer—Part 1: Epidemiology, presentation, and preservation. *Clinical Otolaryngology*, 36(1), 65-68.
- El-Mofty, S. (2010). Early detection of oral cancer. *Egypt J Oral Maxillofac Surg* .1: 25-31.
- Wood, W.C., Moore, S., Staley, C., Skandalakis, J.E. (2010). *Anatomic Basis of Tumor Surgery*: Springer.
- Moore, M. A., Ariyaratne, Y., Badar, F., Bhurgri, Y., Datta, K., Mathew, A., ... & Yeole, B. B. (2010). Cancer epidemiology in South Asia-past, present and future. *Asian Pac J Cancer Prev*, 11(Suppl 2), 49-66.
- Güven, O. (1998). A clinical study on oroantral fistulae. *Journal of cranio-maxillofacial surgery*, 26(4), 267-271.
- El-Hakim, I. E., & El-Fakharany, A. M. (1999). The use of the pedicled buccal fat pad (BFP) and palatal rotating flaps in closure of oroantral communication and palatal defects. *The Journal of Laryngology & Otology*, 113(9), 834-838.
- Zhang, H. M., Yan, Y. P., Qi, K. M., Wang, J. Q., & Liu, Z. F. (2002). Anatomical structure of the buccal fat pad and its clinical adaptations. *Plastic and reconstructive surgery*, 109(7), 2509-18.
- Mohan, S., Kankariya, H., & Harjani, B. (2012). The use of the buccal fat pad for reconstruction of oral defects: review of the literature and report of cases. *Journal of maxillofacial and oral surgery*, 11(2), 128-131.
- Hazrati, E., Loh, F. C., & Loh, H. S. (1992). Use of the buccal fat pad for correction of intraoral defects. *Plastic and Reconstructive Surgery*, 90(1), 151.
- Bither, S., Halli, R., & Kini, Y. (2013). Buccal fat pad in intraoral defect reconstruction. *Journal of maxillofacial and oral surgery*, 12(4), 451-455.
- Hao, S. P. (2000). Reconstruction of oral defects with the pedicled buccal fat pad flap. *Otolaryngology—Head and Neck Surgery*, 122(6), 863-867.
- Mehta, S., Sarkar, S., Kavarana, N., Bhathena, H., & Mehta, A. (1996). Complications of the pectoralis major myocutaneous flap in the oral cavity: a prospective evaluation of 220 cases. *Plastic and reconstructive surgery*, 98(1), 31-37.
- Hsing, C. Y., Wong, Y. K., Wang, C. P., Wang, C. C., Jiang, R. S., Chen, F. J., & Liu, S. A. (2011). Comparison between free flap and pectoralis major pedicled flap for reconstruction in oral cavity cancer patients—a quality of life analysis. *Oral oncology*, 47(6), 522-527.
- Liu, H. L., Chan, J. Y. W., & Wei, W. I. (2010). The changing role of pectoralis major flap in head and neck reconstruction. *European Archives of Oto-Rhino-Laryngology*, 267(11), 1759-1763.
- Bagan, J. V., Murillo, J., Poveda, R., Gavalda, C., Jimenez, Y., & Scully, C. (2004). Proliferative verrucous leukoplakia: unusual locations of oral squamous cell carcinomas, and field cancerization as shown by the appearance of multiple OSCCs. *Oral oncology*, 40(4), 440-443.
- Cerero-Lapiedra, R., Baladé-Martínez, D., Moreno-López, L. A., Esparza-Gómez, G., & Bagán, J. V. (2010). Proliferative verrucous leukoplakia: a proposal for diagnostic criteria. *Med Oral Patol Oral Cir Bucal*, 15(6), e839-45.
- Veeresh, M., & Mahesh, K. B. (2012). "Commando Surgery" for Carcinoma of Retromolar Trigone: A Case Report with Review of Literature. *RGUHS Journal of Medical Sciences*, 2(2), 109-112.
- Navarro, C. M., Sposto, M. R., Sgavioli-Massucato, E. M., & Onofre, M. A. (2004). Transformation of proliferative verrucous leukoplakia to oral carcinoma: a ten years follow-up. *Medicina oral: organo oficial de la Sociedad Espanola de Medicina Oral y de la Academia Iberoamericana de Patologia y Medicina Bucal*, 9(3), 229-233.
- Kresty, L. A., Mallery, S. R., Knobloch, T. J., Li, J., Lloyd, M., Casto, B. C., & Weghorst, C. M. (2008). Frequent alterations of p16INK4a and p14ARF in oral proliferative verrucous leukoplakia. *Cancer Epidemiology and Prevention Biomarkers*, 17(11), 3179-3187.