

Fiberoptic Assisted Repair of Cut Throat Injury- A Case Report

Manu C B¹, Gowri Sankar M^{2*}, Sabharisan P³, Karthikeyan R⁴, Sivaraman G⁵

^{1, 3} Junior resident, Dept. of ENT, JIPMER, Dhanvantri Nagar, Gorimedu, Jipmer Campus, Puducherry, Tamil Nadu, India

^{2, 4} Senior resident, Dept. of ENT, JIPMER, Dhanvantri Nagar, Gorimedu, Jipmer Campus, Puducherry, Tamil Nadu, India

⁵ Associate Professor, Dept. of ENT, JIPMER, Dhanvantri Nagar, Gorimedu, Jipmer Campus, Puducherry, Tamil Nadu, India

*Corresponding author

Gowri Sankar M

Article History

Received: 09.03.2018

Accepted: 20.03.2018

Published: 17.03.2018

DOI:

10.36348/sjm.2018.v03i03.001



Abstract: Cut throat injuries are usually homicidal rather than suicidal, presenting with challenging air way compromise and blood loss secondary to damage of vital structures in the neck. We present a case of cut throat injury- a suicidal attempt of a psychologically normal young adult in attempt to pacify his family dispute which was repaired with the assistance of fiberoptic endoscopy.

Keywords: Cut throat injury, fiberoptic assisted.

INTRODUCTION

Suicide is one of the 10 leading causes of death in the world with 1 million deaths occurring annually [1]. Laceration of the forearm or wrists being the most common method of self-injury while the other modes of injury are firearm, hanging, ingestion of toxic substance, while suicidal cut throat injury (CTI) being a rare entity [2]. Cut throat injuries are usually homicidal rather than suicidal, presenting with challenging air way compromise and blood loss secondary to damage of vital structures in the neck. We present this case of cut throat injury which was a suicidal attempt of a psychologically normal young adult in attempt to pacify his family dispute.

CASE REPORT

A 25 yr old male presented to the emergency department with alleged history of suicide by cutting the anterior neck with a kitchen knife, 4hrs after the incident.

On examination, patient was conscious, vitals stable with bilateral equal air entry in the lung fields. Neck examination showed a clean incised wound with irregular lower margins, measuring 7cm horizontally at the level of lower border of thyroid cartilage extending from anterior border of one sternomastoid to the other with platysma being breached falling under zone II Roon and Christensen's classification [3]. Further examination showed fracture of thyroid cartilage (lower 1/3), through which the under surface of vocal cords were seen which were mobile, fortunately with no great vessel injury (Figure-1).

Contrast CT showed minimal surgical emphysema with fracture of the thyroid cartilage with no great vessel or cricotracheal injury (Figure-2).

Patient was planned for neck exploration. A low tracheostomy was done through a horizontal incision under local anesthesia and patient was taken up for neck exploration under general anesthesia.

The strap muscles (sternohyoid) on both the sides were cut in entire breadth. The thyroid cartilage

(both lamina, non-calcified) was cut 2mm from the lower border of thyroid cartilage in its entire breadth with breach in the midline laryngeal mucosa with a defect size of 5mm by 5mm. The cricothyroid membrane and cricoid cartilage were intact with no major vessel injury. A fiberoptic assessment showed a mucosal rent noted immediately below anterior commissure. The mucosal rent was closed extramucosally with 3-0 vicryl suture (2 stitch), closure of the defect verified by fiberoptic scopy verifying no suture material visualized in the subglottic region. The displaced thyroid cartilage was approximated with 2-0 prolene, sternohyoid repaired, hemostasis verified and a suction drain secured. The wound was closed in 2 layers with 3-0 vicryl, skin closed with 3-0 silk and two hammock sutures in neck with 1-0 prolene. A ryles tube was inserted and patient was reversed out of general anaesthesia uneventfully (Figure-3).

On day 2, drain was removed and fiberoptic assessment showed good closure of the mucosal rent with normal vocal cord mobility. Fiberoptic assessment on post-operative day10, showed good closure of the mucosal rent, following which he was started oral

feeds, trial block of tracheostomy done and removal of external neck sutures . Repeat fiberoptic assessment was done on 14th day showing adequate closure of the laryngeal mucosal rent with no stitch related granulations (Figure 4).

He was successfully decannulated on day 15 with no aspiration or leak with a normal voice. He was discharged on day 16 after psychiatric counselling. Patient was followed up for 6 months with no complaints of difficulty in breathing or speech.

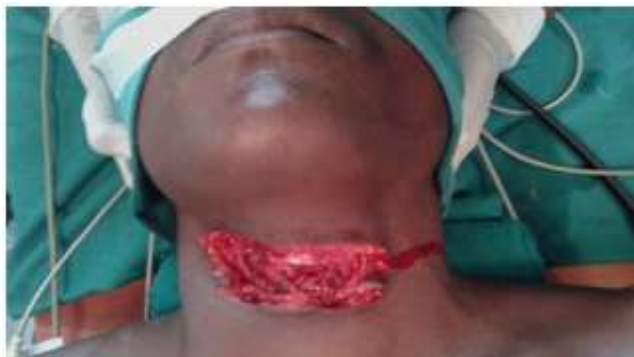

Fig-1: Showing extent of wound with irregular lower margins

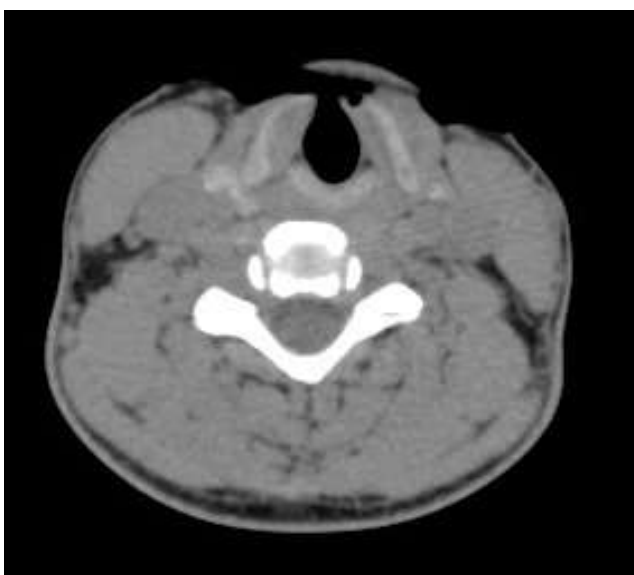


Fig-2: CT showing breach in thyroid cartilage below level of vocal cords

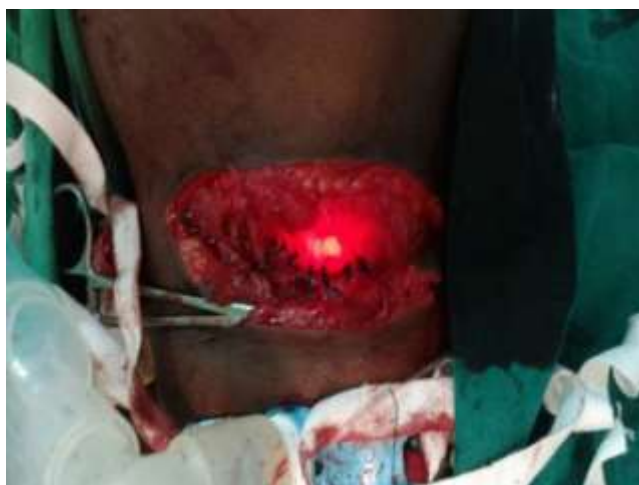

Fig-3: Intra op view (external) after laryngeal framework repair with tip of the fiberoptic scope at the level of laryngeal mucosal defect

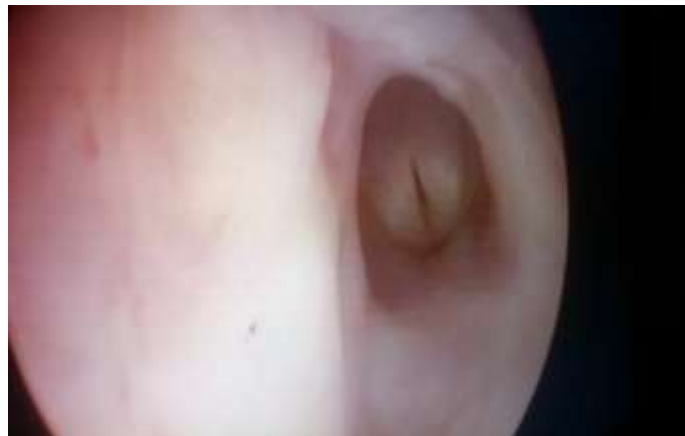

Fig-4: Tracheoscopic view of subglottis on 14th day with no stitch related granulations

DISCUSSION

Evaluation of penetrating injuries of the neck needs stress on the possibility of vital structures being injured like laryngopharynx, trachea-oesophageal complex, major neck vessels, nerve roots or the spinal cord. Clinical examination and investigations need to aid in recognizing any injury to these structures. Investigative procedures should include x-ray of the neck & chest, CT scan, direct laryngoscopy, bronchoscopy, esophagoscopy, barium swallow, and arteriography [4].

A fiberoptic assessment would be an ideal tool as was experienced by us in this case not only for assessing the upper and lower airway from therapeutic aspect but also for documentation of vocal cord status in medico-legal cases prior to exploration and for securing the airway. Fiberoptic assessment may be a problem in the presence of bleeding or secretions. Fearing the possibility of worsening the injury or difficult airway intubation, it is ideally avoided in an airway injury and a temporary tracheostomy preferred mainly to by-pass airway edema and the need for prolonged secured airway. The tool had the added advantage of verifying the position of extramucosal sutures thus avoiding the chances of stitch granulation in the laryngeal mucosa which may progress to subglottic stenosis. This enabled us to decannulate the patient early.

Bryce keeps the head of patient in flexed position post-operatively for 7 to 10 days by means of a suture from the chin to the sternum to relieve tension on the anastomotic site which was followed by us. Psychiatric counselling and medications are an important aspect in the management of suicidal events but did not play a major role in our case as he was emotionally stable and the event occurred to pacify family dispute.

CONCLUSION

In a case of transected thyroid cartilage, secure the airway with a tracheostomy below the injury, repair

by primarily anastomosing and then maintain the neck in flexion to aid in tension free anastomosis. This technique provides a patent non-compromised airway and a relatively simple surgical technique which can be performed even in peripheral hospitals.

ACKNOWLEDGMENTS

Financial acknowledgments or non- Financial acknowledgments: none

REFERENCES

1. Gleeson, M. J., & Clarke, R. C. (Eds.). (2008). *Scott-Brown's Otorhinolaryngology: Head and Neck Surgery 7Ed: 3 volume set*. CRC Press.
2. Sharma, K., Kakati, K., Goswami, S. C., Bhagawati, D., & Krishnatreya, M. (2013). A study on behavior and management of suicidal cut throat patients. *J Laryngol Voice*;3:57-60.
3. Joshi, S. S., Jagade, M., Nichalani, S., Bage, S., Agarwal, S., & Pangam, N. (2013). Technicality of managing cut throat injury. *International journal of otolaryngology and head & neck Surgery*, 2(01), 11.
4. Bryce, D. P. (1972). The surgical management of laryngotracheal injury. *The Journal of Laryngology & Otology*, 86(6), 547-587.