

Invasive Nasal Aspergillosis: A Case of an Agressif Pseudo Tumoral Form

El Messaoudi Lina^{1, 3*}, Al rajab Soundos^{1, 3}, Ahmed Khayri^{1, 3}, Nitassi Sophia^{2, 3}, Bencheikh Razika^{2, 3}, Benbouzid Mohamed Anas^{2, 3}, Oujilal Abdelhamid^{2, 3}, Leila Essakalli Houssyni^{2, 3}

¹Resident Physician in Otorhinolaryngology, Department of Otorhinolaryngology, Head and Neck Surgery, Ibn Sina University Hospital, Rabat, Morocco

²Professor of Otorhinolaryngology, Department of Otorhinolaryngology, Head and Neck Surgery, Ibn Sina University Hospital, Rabat, Morocco

³Faculty of Medicine and Pharmacy of Rabat, Mohammed V University, Rabat, Morocco

DOI: [10.36348/sjmps.2021.v07i11.004](https://doi.org/10.36348/sjmps.2021.v07i11.004)

| Received: 12.09.2021 | Accepted: 23.10.2021 | Published: 04.11.2021

*Corresponding author: El Messaoudi Lina

Abstract

Aspergillosis of the nasal and paranasal sinuses is recognized as being second to candidiasis, among opportunistic fungal infections in immunocompromised patients. However, invasive variant in normal and mildly immunocompromised hosts is a very rare occurrence. We report a new observation of nasal sinus aspergillosis in its pseudotumoral form.

Keywords: Rhinosinusitis, Aspergillus, Mycology, Endoscopic surgery.

Copyright © 2021 The Author(s): This is an open-access article distributed under the terms of the Creative Commons Attribution **4.0 International License (CC BY-NC 4.0)** which permits unrestricted use, distribution, and reproduction in any medium for non-commercial use provided the original author and source are credited.

INTRODUCTION

The incidence of fungal rhinosinitis is increasing and the most often criminalized is aspergillus. However, this condition remains in the immunocompetent subject. It is characterized by its invasive pseudotumoral character and the possibility of complications. in the pseudotumoral form with destruction of the sinus bone walls, confusing with tumor lesions. Imaging, in particular CT of the facial mass, plays an indisputable role in the diagnosis and assessment of the extension of the various forms of aspergillary sinusitis. We report in this publication the case of an invasive nasal aspergillosis pseudo-tumor form in a young patient immunocompetent.

CASE REPORT

A 24-year-old male was admitted in the Department of Otorhinolaryngology, Head and Neck Surgery, Ibn Sina University Hospital, Rabat, Morocco in august 2019 for total right nasal obstruction progressively evolving for about 6 months, exophthalmia grad 2 and intense headache, Patient history revealed no systemic diseases and no previous sinonasal surgery; The patient showed no evidence of immunosuppression after biologic investigations. The clinical endoscopic examination found a inflammatory mucosa; right purulent anterior rhinorrhea; with pus from medium meat; the cervical palpation found no palpable lymphadenopathy; a CT scan and MRI of the nasal sinuses and skull was ordered. they showed invasive aspergillary rhinosinusitis with intraorbital extension and doubt about cranial extension (Fig 1).

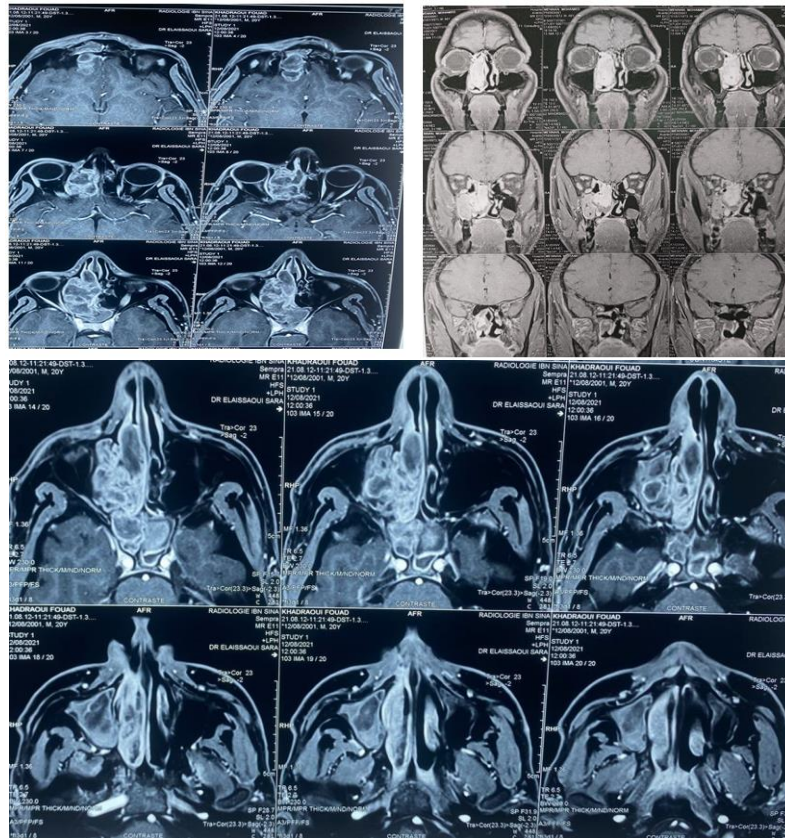


Fig 1

The patient underwent endonasal surgery(“ in the presence of a team of neurosurgeons with our orl team; Purulence (Fig 2) was observed during the operation. A biopsy (Fig 3) was performed immediately and histopathology examination revealed *Aspergillus* species. The patient was administered fluconazole after surgery. Post-operative neurological examination showed obvious improvement of headache, vomiting, vision, and diplopia. Post-operative images indicated the resection of the mass. Examination after a follow-up period of 12 months showed no clinical symptoms, and no additional therapy was required.

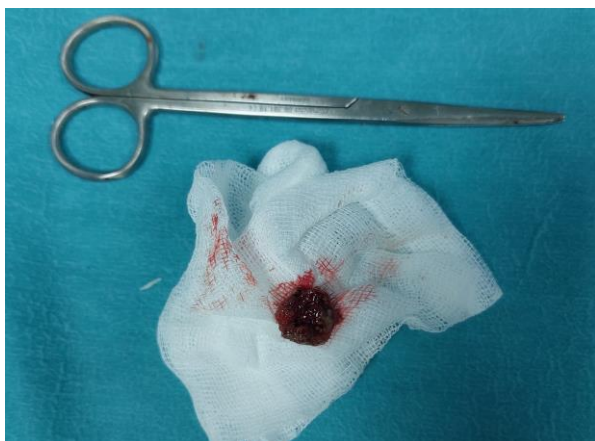

Fig 2

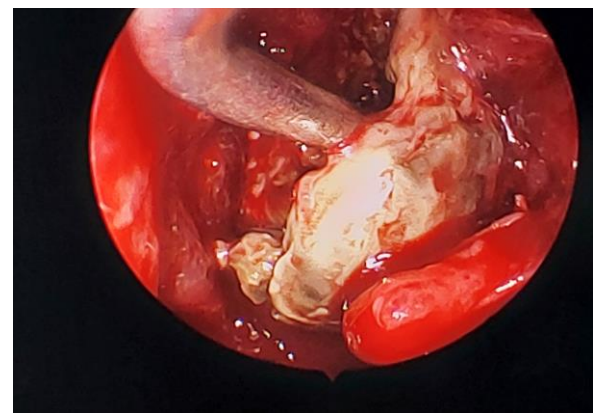


Fig 3

DISCUSSION

Fungal infections of the paranasal sinuses need to be recognised in order to avoid significant mortality and morbidity. Suspicion can arise in cases of purulent rhinosinusitis which do not respond to two or more courses of antibiotics, and on the basis of radiological features. Most invasive aspergillosis is caused by *A. fumigatus* (80-90%); *A. flavus* (5-10%), *A. niger* (1-5%) and *A. terreus* (1%) are less common [4]. *Aspergillus fumigatus* is the most common organism in immunocompetent patients too. Predisposing factors that promote fungal infections in the sinuses include polyps and stagnant secretions besides other factors like neutropenia, inappropriate use of antibiotics,

immunosuppressive drugs, corticosteroids, uncontrolled diabetes mellitus, human immunodeficiency virus infection, trauma, burns, and radiation therapy [6]. Invasive aspergillosis is a major cause of death in immunosuppressed patients, particularly following hematopoietic cell transplantation. The clinical presentation is closely related to the form of rhinosinusitis dominated by nasal obstruction, headache, rhinorrhea. Elsewhere, other less common signs (epistaxis, visual or neurological complications) can in some cases reveal the disease. Aspergillosis should be suspected in patients with refractory or recurrent sinusitis. Invasive aspergillosis originating from the nose and paranasal sinuses can cause an intra-orbital and intra-cranial growth mainly along the skull base and larger vessels. If the orbit becomes involved, additional symptoms may include blurred vision, gradual loss of vision, chemosis and proptosis. The infection can also extend locally into the vasculature and the brain, leading to cavernous sinus thrombosis and a variety of central nervous system manifestations [7]. Intracranial and intraorbital extension decrease the survival rate and increase surgical morbidity. Both magnetic resonance imaging (MRI) and CT scan can help to establish a diagnosis of invasive fungal sinusitis. Opacity of the sinus with or without destruction may be demonstrated in the invasive form. Although bone erosion and extrasinus extension are the classic CT findings highly suggestive of invasive fungal sinusitis, these are usually found late in the course of the disease; the most common early sign is severe unilateral nasal cavity mucosal and soft tissue edema. Bone involvement and erosion is more delineated on CT, while soft tissue extensions, vascular invasion and cavernous sinus involvement are more appreciated on MRI [1]. Clinicoradiological findings can be misleading as the lesions are locally destructive and mimic a neoplasm. Biopsy is necessary to establish the diagnosis. Hyphae are typical and specific for each fungus; Mucor presents large, broad non-septate hyphae with right-angle branching, and Aspergillus shows septate hyphae that branch at 45° angles. The histology should be specific as to whether there is mucosal involvement (invasive) or the mucosa is intact (non-invasive disease). Fungal cultures on Sabouraud's dextrose agar are needed to confirm the diagnosis. Management of invasive aspergillosis therapy is still controversial and depends on several factors such as the nature of the disease, host immunity and degree of tissue invasion. Response to treatment depends on early diagnosis and initiation of antifungal therapy augmented by surgical debridement. Surgical debridement of abnormal tissue in the sinus is recommended for pharmacological therapy to reach the infected area. Surgery may improve the control of fungal disease and patient survival. The Infectious Diseases Society of America (IDSA) released updated guidelines for the treatment of invasive aspergillosis in 2008. Voriconazole (broad-spectrum triazole) has now

become the drug of choice for invasive aspergillosis [9]. This is due to a better tolerance, increased efficacy (with a greater likelihood of a complete or partial response), improved survival (with a lower mortality rate), and significantly less toxicity when compared with amphotericin B [10]. Only a few case reports have described the clinical course of invasive fungal sinusitis treated with voriconazole. The duration of therapy depends on several factors such as the location of the infection, the patient's underlying disease and the need for further immunosuppression, and the response to therapy. For most patients, antifungal therapy will continue for months or even years in some cases. Regular post-operative follow-up is recommended in all the cases with CT scan and nasal endoscopy every 3-4 months. Early diagnosis of recurrent disease requires prolonged systemic antifungal chemotherapy.

CONCLUSION

Pseudo tumoral invasive aspergillosis is a pathology rare and potentially serious. Evolution is unpredictable and the prognosis depends mainly on the earliness of the diagnosis and the speed of treatment.

REFERENCES

1. Agarwal, S., Kanga, A., Sharma, V., Sharma, D. R., & Sharma, M. L. (2005). Case Report-Invasive aspergillosis involving multiple paranasal sinuses-A case report. *Indian journal of medical microbiology*, 23(3), 195-197.
2. Safirstein, B. H. (1976). Allergic bronchopulmonary aspergillosis with obstruction of the upper respiratory tract. *Chest*, 70(6), 788-790.
3. Barclay, L., & Lie, D. (2006). Diagnosis of allergic fungal rhinosinusitis clarified. *Arch Oto Laryngol Head Neck Surg*, 132, 173-178.
4. Udaipurwala, I. H. (2008). Allergic fungal sinusitis: a perplexing clinical entity. *Pak J Otolaryngol*, 24, 25-27.
5. Stammberger, H., Jakse, R., & Beaufort, F. (1984). Aspergillosis of the paranasal sinuses: X-ray diagnosis, histopathology, and clinical aspects. *Annals of Otolaryngology, Rhinology & Laryngology*, 93(3), 251-256.
6. Dayananda, B. C., Vandana, R., Rekha, K., & Kumar, G. S. (2002). Aspergillosis of the maxillary antrum: A case report. *J Oral Maxillofac Pathol*, 1, 26-29.
7. Denning, D. W. (1998). Invasive aspergillosis. *Clinical infectious diseases*, 781-803.
8. Regezi, J. A., Sciubba, J. J., & Jordan, R. C., editors. (2003). *Ulcerative conditions. Oral pathology-Clinical Pathologic Correlations*. 4th ed. Missouri: Saunders - An Imprint of Elsevier Science; p. 23-74.
9. Chambers, M. S., Lyzak, W. A., Martin, J. W., Lyzak, J. S., & Toth, B. B. (1995). Oral complications associated with aspergillosis in

- patients with a hematologic malignancy: Presentation and treatment. *Oral Surgery, Oral Medicine, Oral Pathology, Oral Radiology, and Endodontology*, 79(5), 559-563.
10. Veress, B., Malik, O. A., El Tayeb, A. A., El Daoud, S., Mahgoub, E. S., & El Hassan, A. M. (1973). Further observations on the primary paranasal aspergillus granuloma in the Sudan: A morphological study of 46 cases. *The American journal of tropical medicine and hygiene*, 22(6), 765-772.
11. Samaranayake, L. P., Leung, W. K., & Jin, L. (2009). Oral mucosal fungal infections. *Periodontology 2000*, 49(1), 39-59.
12. Rowe-Jones, J. M., & Moore-Gillon, V. (1994). Destructive noninvasive paranasal sinus aspergillosis: component of a spectrum of disease. *The Journal of otolaryngology*, 23(2), 92-96.
13. Myoken, Y., Sugata, T., Fujita, Y., Fujihara, M., Iwato, K., Murayama, S. Y., & Mikami, Y. (2006). Early diagnosis and successful management of atypical invasive Aspergillus sinusitis in a hematopoietic cell transplant patient: a case report. *Journal of oral and maxillofacial surgery*, 64(5), 860-863.
14. Neville, B. W., Damm, D. D., Allen, C. M., & Bouquot, J. E. (2005). Fungal and protozoal diseases. *Oral and Maxillofacial Pathology*. 2nd ed. Pennsylvania: Saunders - An Imprint of Elsevier; 189-211.
15. Lin, S. J., Schranz, J., & Teutsch, S. M. (2001). Aspergillosis case-fatality rate: systematic review of the literature. *Clinical infectious diseases*, 32(3), 358-366.
16. Nikolaizik, W. H., Weichel, M., Blaser, K., & Cramer, R. (2002). Intracutaneous tests with recombinant allergens in cystic fibrosis patients with allergic bronchopulmonary aspergillosis and Aspergillus allergy. *American journal of respiratory and critical care medicine*, 165(7), 916-921.
17. Hartl, D., Latzin, P., Zissel, G., Krane, M., Krauss-Etschmann, S., & Griese, M. (2006). Chemokines indicate allergic bronchopulmonary aspergillosis in patients with cystic fibrosis. *American journal of respiratory and critical care medicine*, 173(12), 1370-1376.
18. Kraemer, R., Deloséa, N., Ballinari, P., Gallati, S., & Cramer, R. (2006). Effect of allergic bronchopulmonary aspergillosis on lung function in children with cystic fibrosis. *American journal of respiratory and critical care medicine*, 174(11), 1211-1220.
19. Frisvad, J. C., Rank, C., Nielsen, K. F., & Larsen, T. O. (2009). Metabolomics of Aspergillus fumigatus. *Medical Mycology*, 47(sup1), S53-S71.