

Metastatic Follicular Thyroid Carcinoma to the Maxilla: A Case Report

Sarra Azzez^{1*}, Yassine Oueslati¹, Sameh Sioud¹, Hajer Hentati¹, Habib Hamdi¹, Jamil Selmi¹

¹Department of Oral medicine and oral surgery, University Dental Clinic of Monastir, University of Monastir, Tunisia

DOI: [10.36348/sjimps.2021.v07i10.007](https://doi.org/10.36348/sjimps.2021.v07i10.007)

| Received: 08.09.2021 | Accepted: 13.10.2021 | Published: 21.10.2021

*Corresponding author: Sarra Azzez

Abstract

Metastatic tumors to the oral cavity affecting either the jaws or the soft tissue are unusual and accounts approximatively for 1% of all oral malignant neoplasms. Moreover, a thyroid primary tumor is considered almost rare. The present paper describes a case of metastatic follicular thyroid carcinoma to the right maxillary sinus, bone and alveolar mucosa in a 73-year-old male patient. Our aim is to highlight the importance of considering oral metastasis in the diagnosis of jaws and soft tissue lesions especially in patients with known primary malignant tumor.

Keywords: Thyroid carcinoma, Maxilla, Follicular, Oral metastasis.

Copyright © 2021 The Author(s): This is an open-access article distributed under the terms of the Creative Commons Attribution **4.0 International License (CC BY-NC 4.0)** which permits unrestricted use, distribution, and reproduction in any medium for non-commercial use provided the original author and source are credited.

INTRODUCTION

Metastases occurrence in the oral cavity are extremely rare and constitute nearby 1% of all malignant tumors. The most common primary cancers are the lung, prostate and liver for man and the breast, kidney and colo-rectum for woman [1].

Few cases of Thyroid carcinoma metastases to the jaws were reported in the literature. It is uncommon and accounts for 3% of all jaws metastases [2].

Follicular thyroid carcinoma (FTC) is the second most common histologic variant of thyroid cancer, representing from 10% to 20% of all thyroid malignancies. It affects individuals with mean age of 50 years. It's characterized by an aggressive behaviour, high potential of distant metastasis through hematogenous dissemination and poor prognosis [3].

We report an original case of FTC metastasizing to the maxilla affecting both hard and soft tissue in a 73-year-old man. Our aim is to emphasize

the need to be vigilant in cases with a history of malignant tumor.

CASE REPORT

A 73-year-old man was referred in September 2020 by his general practitioner to the department of oral medicine and oral surgery at the University Dental Clinic of Monastir-Tunisia. The reason was a maxillary rapidly growing mass.

The patient denied any tobacco or alcohol consumption or betel quid chewing. He declared that he was diagnosed with follicular thyroid carcinoma and treated with thyroidectomy and high-dose radioiodine therapy years ago. He complained about paraesthesia, inability to eat or drink and pain in the right maxillary region. The extraoral examination didn't reveal any cervical lymph nodes. The general physical examen was non-contributory. We noticed that the patient couldn't close properly his mouth due to the intra-oral mass (Figure 1).

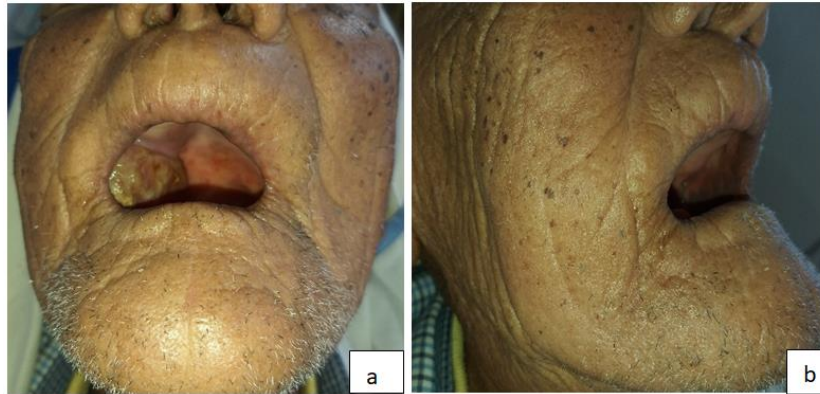


Figure 1: Extraoral views : (a) a facial asymmetry, (b) the patient couldn't close his mouth

The intraoral examination showed a limitation of mouth opening. The patient was completely edentulous. Mucosal irregular, firm and exophytic mass

of the right maxillary alveolar ridge was noticed. It was painful and measured 3 cm in diameter covered by ulcerative mucosa (Figure 2).

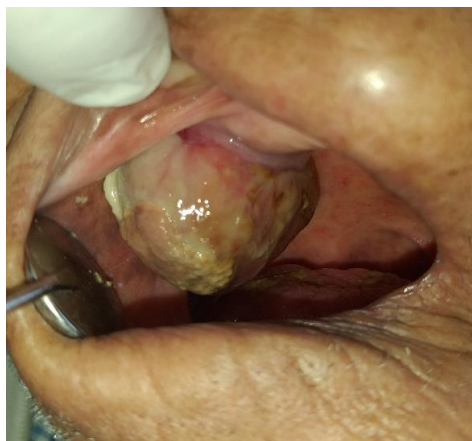

Figure 2: Intraoral view showing a sessile, soft tissue mass of the right maxillary region

Given the malignant aspect, a computed tomography (CT) Scan was directly requested for the patient. It demonstrated an aggressive osteolytic process

with ill-defined borders and highly vascularized affecting the bone, the maxillary sinus and even extending to the nasal cavity (Figure 3).

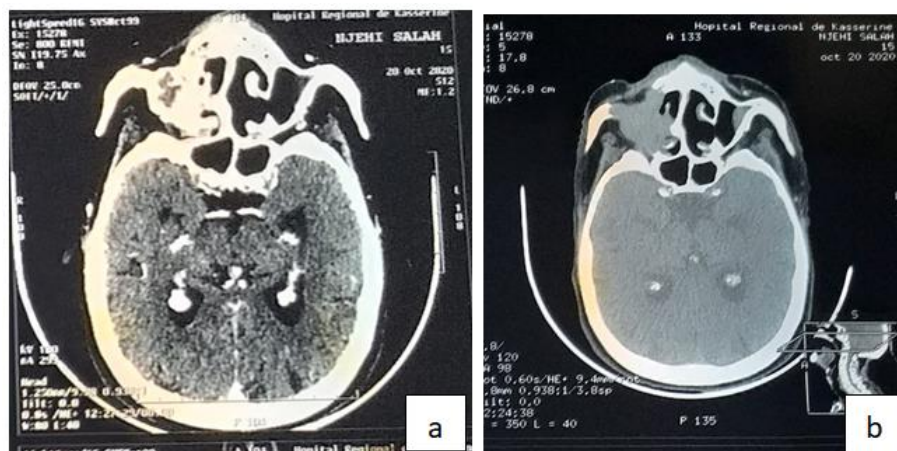


Figure 3: CT scan : axial cuts showing an aggressive process infiltrating the maxillary sinus and jaw, (a) after injection of contrast product, (b) narrow window

An incisional biopsy was performed. The histopathological examination revealed thyroid follicles

filled with colloid material (Figure 4). Immunohistochemical examinations revealed tumor

cells positivity against thyroglobin, keratin 19 and pancytokeratin. These characteristics fit well with the primary thyroid tumor features. So, based on these findings, a final diagnosis of metastatic FTC to maxilla was made.

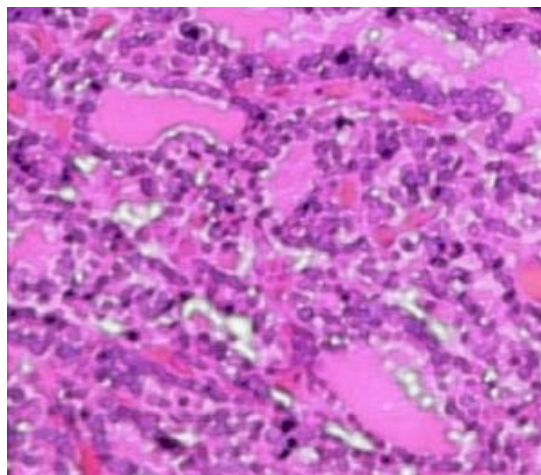


Figure 4: Histological examination showing thyroid follicles filled with colloid material (HE stain x 100)

Immediately, the patient was referred to ear, nose and throat department. A whole-body bone scan and positron emission tomography-CT (PET-CT) was performed and it has revealed other metastatic lesions in the sternum and ribs. A palliative radiation therapy was suggested for the patient after multidisciplinary team discussion given the disseminated nature of the tumor.

DISCUSSION

Distant metastasis of thyroid carcinoma is rare. Lung and bone (Sternum, vertebrae, pelvis and ribs) are the typical metastatic sites whereas the oral cavity is rarely involved [4, 5]. It represents nearby 3% of all oral metastatic carcinomas [6]. Although thyroid carcinomas usually affect women more often than men, equal distribution of metastases has been found [7].

The mandible is more commonly affected than the maxilla, with the posterior region being the most frequent site of metastasis. The maxilla represents the target site in less than 20% of all oral metastasis of the jaw [5,7]. It is known that follicular thyroid carcinomas are more sensitive to hematogenous spread in advanced forms. That could explain why the posterior part of the mandible, located directly along the inferior alveolar vessel, is a predilection site [7]. In addition, our patient's presentation also demonstrated this observation. In fact, in our case the spread of malignancy to the maxilla without any lymphadenopathy found indicated the hematogenous path of metastasis. For this case herein, no sign of tumors was found among the lymph node groups of the cervical region.

Moreover, not only does this type of carcinoma spread through a hematogenous pathway, but it also has a tendency to grow to an extremely vascularized form of tumor in its advanced stages [5] such our case.

Clinically, the metastatic tumors of the jaw mainly presents with intraoral or extraoral facial swelling accompanied by pain and paresthesia in the affected region [8]. Radiography, they appear as an osteolytic lesion with irregular, poorly defined borders [9].

The soft tissue localization accounts for only 0.1% of all oral malignancies with attached gingiva affection estimated for 54% of cases [10]. The mucosal metastatic lesions might imitate an hyperplastic lesions such as a pyogenic granuloma, peripheral giant cell granuloma or even more an epulis [6, 10]. This fits our case as the soft tissue affection had the appearance of a peripheral giant granuloma on first intraoral view.

Most of the time, oral metastasis is associated with second localizations and multifocal involvement of other body organs [11]. On our patient's presentation, metastases to other skeletal structures were found.

The management of metastatic carcinoma requires considering both the metastatic site and the primary tumor if simultaneously discovered. The most widely treatment used for the FTC is often high-dose of radioiodine therapy or/ and thyroidectomy, as it was done in our case. When bone metastasis are here, the radiotherapy is recommended [12]. They can be also treated via surgical resection, radiation therapy, or a combination. The treatment of our patient was carried out with radiotherapy. The surgical resection can't be indicated as the oral metastasis was widespread and inoperable.

Known by its high mortality rate, the prognosis of FTC depends on many factors such age, size, vascular invasion and distant metastasis. The studies have reported an overall 5-year survival rate of 40% for bone metastasis of differentiated thyroid [5, 13]. In a systematic review literature of 59 cases of thyroid cancer with facial skeleton metastasis, the overall survival rate at 5 years was 59% [14]. Because of their rarity, the incidence of metastatic follicular thyroid carcinoma is unknown and treatment of this type of carcinoma can be a clinical dilemma. Early diagnosis and adequate surgical and radiological treatment are crucial to ameliorate the long-term survival of these patients. Moreover, a multidisciplinary team collaboration is therefore recommended for a successful management of metastatic follicular thyroid carcinoma.

CONCLUSION

Although metastatic oral diseases are uncommon, this case draws attention to the importance of being vigilant and to consider a metastatic origin of any oral soft tissue mass especially in a patient with known primary malignant tumor. In addition, the oral manifestation might be the first sign for an underlying disseminated disease. Such a presentation requires a meticulous examination of all clinical, radiologic and histological parameters to get the primary cancer.

The poor prognosis furthermore emphasizes the necessity of early diagnosis in order to improve the survival rate.

REFERENCES

1. Wang, W. C., Tseng, C. H., Su, C. W., & Chen, Y. K. (2020). Metastasis of thyroid carcinoma to the buccal mucosa. *Journal of dental sciences*, 15(1), 112-113.
2. Ismail, S. B., Abraham, M. T., Zaini, Z. B., Yaacob, H. B., & Zain, R. B. (2009). Metastatic follicular thyroid carcinoma to the mandible: a case report. *Cases Journal*, 2(1), 1-3.
3. Pasupula, A. P., Dorankula, S. P. R., Thokala, M. R., & Kumar, M. P. (2012). Metastatic follicular thyroid carcinoma to the mandible. *Indian Journal of Dental Research*, 23(6), 843.
4. Pittas, A. G., Adler, M., Fazzari, M., Tickoo, S., Rosai, J., Larson, S. M., & Robbins, R. J. (2000). Bone metastases from thyroid carcinoma: clinical characteristics and prognostic variables in one hundred forty-six patients. *Thyroid*, 10(3), 261-268.
5. Jeon, Y. T., Kim, C. H., Park, S. M., & Kim, M. K. (2019). Distant metastasis of follicular thyroid carcinoma to the mandible: a rare case report. *Journal of the Korean Association of Oral and Maxillofacial Surgeons*, 45(5), 294-298.
6. Hirshberg, A., Shnaiderman-Shapiro, A., Kaplan, I., & Berger, R. (2008). Metastatic tumours to the oral cavity—pathogenesis and analysis of 673 cases. *Oral oncology*, 44(8), 743-752.
7. Vural, E., & Hanna, E. (1998). Metastatic follicular thyroid carcinoma to the mandible: a case report and review of the literature. *American journal of otolaryngology*, 19(3), 198-202.
8. Hirshberg, A., Berger, R., Allon, I., & Kaplan, I. (2014). Metastatic tumors to the jaws and mouth. *Head and neck pathology*, 8(4), 463-474.
9. Narain, S., & Batra, H. (2011). Metastatic carcinoma of maxilla secondary to primary follicular carcinoma of thyroid gland—a case report. *Indian Journal of Dentistry*, 2(2), 30-32.
10. Siddique, I., Chengot, P., Frewer, J., & Walker, D. (2015). A rare case of gingival metastases from papillary thyroid carcinoma. *International journal of surgery case reports*, 7, 82-84.
11. Nikitakis, N. G., Polymeri, A., Polymeris, A., & Sklavounou, A. (2012). Metastatic papillary thyroid carcinoma to the maxilla: case report and literature review. *Head and neck pathology*, 6(2), 216-223.
12. McHenry, C. R., & Phitayakorn, R. (2011). Follicular adenoma and carcinoma of the thyroid gland. *The oncologist*, 16(5), 585-593.
13. Martin, S., Maurice, T., Vathaire, F. D., Catherine, H., Gardet, P., Travagli, J. P., ... & Parmentier, C. (1986). Long-term results of treatment of 283 patients with lung and bone metastases from differentiated thyroid carcinoma. *The Journal of Clinical Endocrinology & Metabolism*, 63(4), 960-967.
14. Varadarajan, V. V., Pace, E. K., Patel, V., Sawhney, R., Amdur, R. J., & Dziegielewski, P. T. (2017). Follicular thyroid carcinoma metastasis to the facial skeleton: a systematic review. *BMC cancer*, 17(1), 1-8.