

# Kayser Fleischer Ring - A Strong Clinical Indicator of Neuro-Wilson's Disease

Ashok Rath<sup>1\*</sup>, Nidhi Singh<sup>2</sup>, R. S. Chauhan<sup>1</sup>, J. P. Chugh<sup>1</sup>

<sup>1</sup>Professor, Regional Institution of Ophthalmology, Pt. B. D. Sharma Post Graduate Institute of Medical Sciences, Rohtak-124001, Haryana, India

<sup>2</sup>Resident, Regional Institution of Ophthalmology, Pt. B. D. Sharma Post Graduate Institute of Medical Sciences, Rohtak-124001, Haryana, India

DOI: [10.36348/sjmpps.2020.v06i06.005](https://doi.org/10.36348/sjmpps.2020.v06i06.005)

| Received: 02.06.2020 | Accepted: 12.06.2020 | Published: 18.06.2020

\*Corresponding author: Dr. Ashok Rath

## Abstract

Wilson's disease is a hereditary disorder of copper metabolism which is characterized by neuropsychiatric and hepatic manifestations as well as appearance of Kayser-Fleischer ring. A male presenting with features of gradually progressive dysphagia, dysarthria, dystonia, abdominal discomfort and difficulty in maintaining balance, was referred for ophthalmic evaluation for any neuro-wilson manifestation. Patient had BCVA of 6/6 both eyes with anterior and posterior segment revealing no significant findings. Slit lamp biomicroscopic examination revealed a yellowish-brown deposits of Kayser Fleischer (KF) Ring following which diagnostic tests for Wilson Disease (WD) were carried out and treated for the same. The dense KF ring conveys that it has been a long-standing disease and a definite indicator of Neuro-wilson disease. This case report emphasize on the significance of early identification of KF ring and its neurological relevance.

**Keywords:** Kayser Fleischer Ring, Wilson Disease, dysphagia, dysarthria, dystonia, autoimmune disease, Neuro-wilson disease.

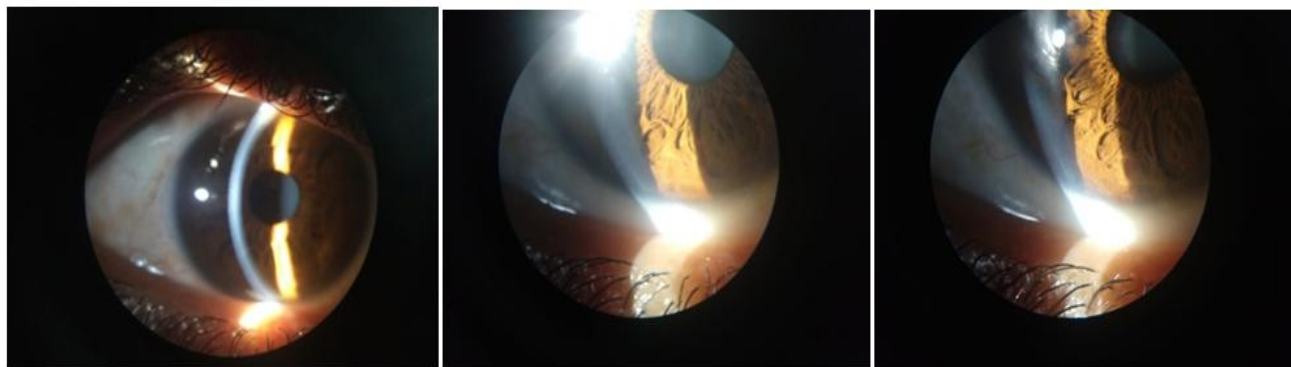
**Copyright © 2020:** This is an open-access article distributed under the terms of the Creative Commons Attribution license which permits unrestricted use, distribution, and reproduction in any medium for non-commercial use (NonCommercial, or CC-BY-NC) provided the original author and source are credited.

## INTRODUCTION

Wilson disease (WD) is a genetic disorder, in which there is an inherited defect in the biliary excretion of copper due to which copper accumulates in the liver, brain, cornea, and other organs resulting in hepatic, neurological/psychiatric, eye, and other manifestations [1, 2]. Wilson disease is a medical condition with a wide spectrum of clinical manifestations. It is one of the common conditions for which clinical opinion of an ophthalmologist is sought. The accumulated copper on Descemet's membrane (DM) of the peripheral cornea is called Kayser Fleischer (KF) ring. KF ring is named after German ophthalmologists Bernhard Kayser (1902) and Bruno Fleischer (1903), who described it independently [3]. The KF ring which is the ocular hallmark of WD is characterized by deposition of copper on the descemet's membrane of the cornea at the periphery [4-6]. Diagnosis of WD is based on at least two of the following: Detection of KF rings on slit lamp biomicroscopy (SL) examination, typical neurological/hepatic symptoms, and/or a low serum ceruloplasmin [6, 7].

## A CASE REPORT

A 28 years male with follow up case of Wilson disease was referred for ophthalmological evaluation to rule out Keyser Fleischer (KF) ring in the cornea-unit. Patient had progressive dysphagia, dysarthria, dystonia, abdominal discomfort and loss of imbalance. The patient was admitted to the medical indoor for a diagnostic work-up as well as treatment for neuro wilson disease. Subsequent work up revealed had lower serum ceruloplasmin (9.18mg/dl) and normal serum copper levels, but had an elevated urine copper of 126.38mcg/ml (normal is 2-80), and an elevated urine copper excretion of 164.29mcg/day (normal is 3-50) after penicillamine excretion test. The best corrected visual acuity was 6/6 in both eyes. The anterior and posterior segments revealed no significant findings. On slit lamp biomicroscopic examination, there was bilateral characteristic yellowish-brown granular deposition at level of Descemet's membrane suggestive of KF ring. This granular deposit of copper was more in the superior and inferior peripheral region of descemet's membrane. KF ring has been described as a pathognomonic sign of neuro-wilson's disease.



## DISCUSSION

Kayser Fleischer rings are seen in most of the patients with neurologic involvement from Wilson disease. However, it may not be seen in approximately 5% of these patients. Kayser Fleischer rings are caused by deposition of excess copper on the inner surface of the cornea in the Descemet's membrane extending to the trabecular meshwork. Copper is deposited as a granular complex with sulfur which gives a ring its characteristic color. It is to be noted that copper is present throughout the cornea, however, due to fluid streaming, copper tends to accumulate superiorly and inferiorly, before involving the iris circumferentially. Copper can also be deposited in the lens in the anterior and posterior capsule causing sunflower cataracts which have radiating centrifugal extensions [8-11].

Neurological onset in WD has been recorded in children as young as 6 years and in adults as old as 52 years [12]. Neurological symptomatology is generally limited to the motor system, presenting as manifestations of extra pyramidal or cerebellar dysfunction [13]. Neurological symptoms are usually secondary to cerebral copper accumulation, which is sufficient to destroy the nerve cells. Predominant presentation includes dystonia, tremor, dysphasia, dysarthria, gait and limb ataxia, and neuropsychiatric manifestations. Histopathological studies in WD have shown atrophy, spongy softening, cavitations, general reduction in neurons and increased cellularity in basal ganglia [14]. Kayser-Fleischer rings are present in almost all the patients in the neurological stage of the disease.

**Source of Support:** None

**Conflict of Interest:** Competing interests: None

## REFERENCES

- Behari, M., & Pardasani, V. (2010). Genetics of Wilson's disease. *Parkinsonism & related disorders*, 16(10), 639-644.
- European Association For The Study Of The Liver. (2012). EASL clinical practice guidelines: Wilson's disease. *Journal of hepatology*, 56(3), 671-685.
- Harry, J., & Tripathi, R. (1970). Kayser-Fleischer ring. A pathological study. *The British journal of ophthalmology*, 54(12), 794-800.
- Manolaki, N., Nikolopoulou, G., Daikos, G. L., Panagiotakaki, E., Tzetzis, M., Roma, E., ... & Syriopoulou, V. P. (2009). Wilson disease in children: analysis of 57 cases. *Journal of pediatric gastroenterology and nutrition*, 48(1), 72-77.
- Roberts, E. A., & Schilsky, M. L. (2003). A practice guideline on Wilson disease. *Hepatology*, 37(6), 1475-1492.
- Sternlieb, I. (1990). Perspectives on Wilson's disease. *Hepatology*, 12(5), 1234-1239.
- Bandmann, O., Weiss, K. H., & Kaler, S. G. (2015). Wilson's disease and other neurological copper disorders. *The Lancet Neurology*, 14(1), 103-113.
- Grupchev, D. I., Radeva, M. N., Georgieva, M., & Grupcheva, C. N. (2018). In vivo confocal microstructural analysis of corneas presenting Kayser-Fleischer rings in patients with Wilson's disease. *Arquivos brasileiros de oftalmologia*, 81(2), 137-143.
- Telinius, N., Ott, P., & Hjortdal, J. (2017). Comment on Advantages of Anterior Segment Optical Coherence Tomography Evaluation of the Kayser-Fleischer Ring in Wilson Disease. *Cornea*, 36(8), e19.
- Sridhar, M. S., Rangaraju, A., Anbarasu, K., Reddy, S. P., Daga, S., Jayalakshmi, S., & Shaik, B. (2017). Evaluation of Kayser-Fleischer ring in Wilson disease by anterior segment optical coherence tomography. *Indian journal of ophthalmology*, 65(5), 354-357.
- Matsuura, H., Murata, A., Shimazaki, T., & Sogabe, Y. (2017). Kayser-Fleischer ring: Wilson's disease. *QJM: An International Journal of Medicine*, 110(8), 531-531.
- Ross, M. E., Jacobson, I. M., Dienstag, J. L., & Martin, J. B. (1985). Late-onset Wilson's disease with neurological involvement in the absence of Kayser-Fleischer rings. *Annals of Neurology: Official Journal of the American Neurological*

- Association and the Child Neurology Society*, 17(4), 411-413.
13. Oder, W., Grimm, G., Kollegger, H., Ferenci, P., Schneider, B., & Deecke, L. (1991). Neurological and neuropsychiatric spectrum of Wilson's disease: a prospective study of 45 cases. *Journal of neurology*, 238(5), 281-287.
  14. Greenfield, J. G., Adams, H. J., & Duchen, L. W. (1992). Nutritional deficiencies and metabolic disorders. In: Greenfield's neuropathology. Ed's, Greenfield, J. G., Adams, H. J., Duchen, L. W., London, Edward Arnold, 838-40.