

Endocrine and Sonographic Evaluation of Severe Male Factor Infertility: A Descriptive Analysis

Dr. Shakeela Ishrat^{1*}, Dr. Mitu Debnath², Dr. Kazi Shamim Ara³, Dr. Mehnaz Mustary Shume⁴, Dr. Serajoom Munira⁵, Dr. Sabiha Sultana⁶

¹Associate Professor, Department of Reproductive Endocrinology and Infertility, BSMMU, Bangladesh

²⁻⁶Consultant, Department of Reproductive Endocrinology and Infertility, BSMMU, Bangladesh

DOI: 10.36348/sijog.2021.v04i05.008

| Received: 15.04.2021 | Accepted: 25.05.2021 | Published: 29.05.2021

*Corresponding author: Dr. Shakeela Ishrat

Abstract

Objective: The objective of the study was to explore the prevalence of different conditions in infertile men with severe male factor, based on endocrine evaluation and scrotal ultrasound. **Materials and methods:** The retrospective study was carried out on 86 infertile men with azoospermia and severe oligospermia who attended the Male infertility clinic of the department of Reproductive Endocrinology and Infertility of Bangabandhu Sheikh Mujib Medical University. They had evaluation with serum testosterone, follicle stimulating hormone (FSH), luteinizing hormone (LH), prolactin and thyroid stimulating hormone (TSH). In addition they had scrotal ultrasound. **Results:** Most (88.37%) of them had azoospermia. Severe oligospermia was present in 11.63%. Testosterone deficiency was detected in 34.9%. Non-obstructive forms (pre-testicular and testicular causes) comprised 62.8%. Scrotal abnormalities suggestive of obstructive and non-obstructive varieties were overlapping with endocrine diagnoses. **Conclusion:** Majority of men with severe male factor infertility has non-obstructive azoospermia which has poor chance of sperm retrieval for in vitro fertilization and intracytoplasmic sperm injection (IVF-ICSI). Substantial proportion of them has testosterone deficiency which needs to be treated if they do not opt for IVF-ICSI with poor prognosis or donor oocytes.

Keywords: Azoospermia, severe oligospermia, scrotal sonogram, male infertility.

Copyright © 2021 The Author(s): This is an open-access article distributed under the terms of the Creative Commons Attribution 4.0 International License (CC BY-NC 4.0) which permits unrestricted use, distribution, and reproduction in any medium for non-commercial use provided the original author and source are credited.

INTRODUCTION

Infertility has serious psychosocial consequences for the affected couples. Male factor, alone or combined, is responsible for around half of the cases [1]. Azoospermia or the absence of sperm in semen and severe oligospermia or sperm count less than 5 million per milliliter of semen are regarded severe male factor infertility. Azoospermia is the absence of sperm in the ejaculate. Severe quantitative deficiency of sperm in ejaculate has similar etiology and management, so together they constitute severe male factor. The diagnosis is made on analysis of at least two samples of semen more than two weeks apart [2]. Around 10% of cases of male infertility are manifested as azoospermia on semen analysis [3]. According to etiology azoospermia is classified into pre testicular, testicular, and post testicular. Clinically azoospermia is divided into obstructive and non-obstructive azoospermia [4]. Non obstructive azoospermia is associated with spermatogenesis failure and obstructive azoospermia is characterized by normal

spermatogenesis and some obstruction in the seminal tract [3].

Hormone analysis provides some clue to the etiology of azoospermia and severe oligospermia. Impaired spermatogenesis and low sperm count is associated with low testosterone and changes in FSH and LH level. There are three different activation period of hypothalamo-pituitary-gonadal axis in males. The first begins at 8th week of gestation when fetal testes secrete testosterone and anti Mullerian hormone (AMH) to induce masculinization, Wolffian duct differentiation and Mullerian duct regression. The second period extends from 1st week to 6 months of age, postnatal testosterone activation essential for penile growth, descent of testis, prostatic activity and male type behavior. Finally HPO axis is reactivated at puberty to initiate spermatogenesis [5].

GnRH secreted from hypothalamus stimulates anterior pituitary gland to secrete FSH and LH. FSH stimulates germinal epithelium and Sertoli cells to

produce sperm. LH stimulates Leydig cells to produce testosterone. Testosterone is essential for initiation and maintenance of spermatogenesis such as completion of meiosis and spermatid development. Sertoli cells produce inhibin B. LH and FSH are under negative feedback of testosterone and inhibin [4].

A recent review analyzes the interpretations of endocrine abnormalities [1]. Normal testosterone, FSH and LH suggest post-testicular forms that include absence or obstruction of vas deference, retrograde ejaculation etc. Low -normal testosterone combined with high FSH and high LH suggest primary testicular forms with damage to spermatogenesis and Leydig cells in conditions like Klinefelter syndrome or chemo radiotherapy. Normal testosterone with high FSH and normal LH suggest primary testicular forms in which there is damage to spermatogenesis only. The conditions are Y chromosome microdeletions, cryptorchidism etc. Low testosterone combined with low FSH and low LH suggest pre-testicular, central or hypothalamo-pituitary forms which include congenital or acquired hypogonadotropic hypogonadism.

Much scrotal pathology is associated with male infertility. Scrotal ultrasound is a cost effective non-invasive method of detecting these pathologies some of which not elicited by clinical examination. Abnormal findings at scrotal ultrasonogram of infertile males include varicocele, hydrocele, microlithiasis, epididymal cyst, and small testes and absent testis [6]. A combination of high FSH with small testes is predictive of non-obstructive azoospermia [5], which has poorer sperm retrieval rate compared to obstructive azoospermia.

The most appropriate treatment of infertile males with severe male factor is in vitro fertilization and intracytoplasmic sperm injection (IVF-ICSI). The procedure is expensive and may not be feasible for most of the couples. When sperm retrieval fails, use of donor semen is not religiously acceptable to our population. Presumptive diagnosis of causes and appropriate counselling regarding the treatment procedure and prognosis is very important. Endocrine and sonographic evaluation of severe male factor is necessary for noninvasive approach to the diagnoses.

Analysis of the prevalence of different etiologies of severe male factor in our population of infertile males is likely to allow for strategic planning of future management and counselling. The objective of the study was to explore the prevalence of different conditions in infertile men with severe male factor, based on endocrine evaluation and scrotal ultrasound.

MATERIALS AND METHODS

The retrospective study was carried out on 86 infertile men with severe oligospermia and azoospermia who attended the Male infertility clinic at the department of Reproductive Endocrinology and Infertility of Bangabandhu Sheikh Mujib Medical University. They had evaluation with serum testosterone, follicle stimulating hormone (FSH), luteinizing hormone (LH), and prolactin and thyroid stimulation hormone (TSH). In addition they had scrotal ultrasound.

Total testosterone less than 300ng/dl, 3 mg/mL or 10.4015 nmol/L was considered testosterone deficiency or hypogonadism. According to the levels of total testosterone, FSH and LH, the sub fertile males with severe male factor were categorized into following according to Ferlin et al. [1]:

- Group 1 (normal testosterone, normal FSH, normal LH): Post testicular forms
- Group 2 (low or low-normal testosterone, high FSH, high LH): Primary testicular forms (spermatogenesis and Leydig cell damage)
- Group 3 (normal testosterone, high FSH, normal LH): Primary testicular forms (spermatogenesis damage)
- Group 4 (low testosterone, low FSH, low LH): Pretesticular forms.
- Group 5: Unspecified

Statistical analysis was done with SPSS (Statistical Package of Social Sciences), Version 23.

RESULTS

A total of 86 infertile males with severe male factor were analyzed. Most 76/86 (88.37%) of them had azoospermia and only 10/86 (11.63%) of them had severe oligospermia. Baseline characteristics of the participants are described in Table 1.

Hypogonadism was present in 34.9% of sub fertile males with severe male factor (Figure 1). The frequency of different endocrine diagnoses is shown in Figure 2. The most frequent was the primary testicular form (damage to both spermatogenesis and Leydig cells) 34.9% followed by post testicular forms 33.4%. Next in frequency was primary testicular form (only damage to spermatogenesis) 16.3%. Pre testicular causes were least frequent, only 3.5%. The unspecified etiology (11.6%) included those with normal FSH, normal LH and low testosterone. Obstructive or post testicular form comprised 33.7%. Non-obstructive forms included pre-testicular and testicular (damage to spermatogenesis and Leydig cells plus damage to spermatogenesis plus unspecified) which was 62.8%. There was no case of hyperprolactinemia and only one case of hypothyroidism (raised TSH).

Table-1: Baseline characteristics of the study participants (n=86)

Parameters	Mean, SD	Percentage
Age (years)	32.20±5.322	
Residence		
Urban		67.4
Rural		32.6
Socio economic condition (monthly income)		
Low (<120\$)		39.5
Middle (120-240\$)		38.4
High >240\$		22.1
Type of infertility		
Primary		99.3%
Secondary		0.7%
Duration of infertility (years)	6.709±3.8275	

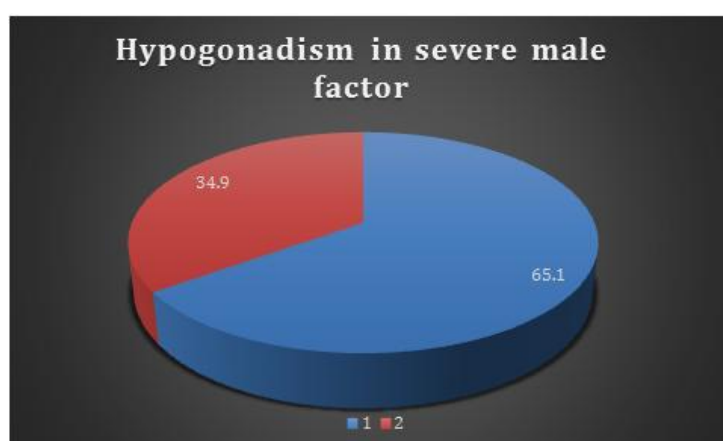


Fig-1: Pie chart showing the prevalence of hypogonadism in sub-fertile males with severe male factor:1. Serum total testosterone normal (>300 ng/dl, >3 ng/mL or >10.4015nmol/L) 2.Serum total testosterone low (<300 ng/dl, <3ng/mL or <1040.15 nmol/L)

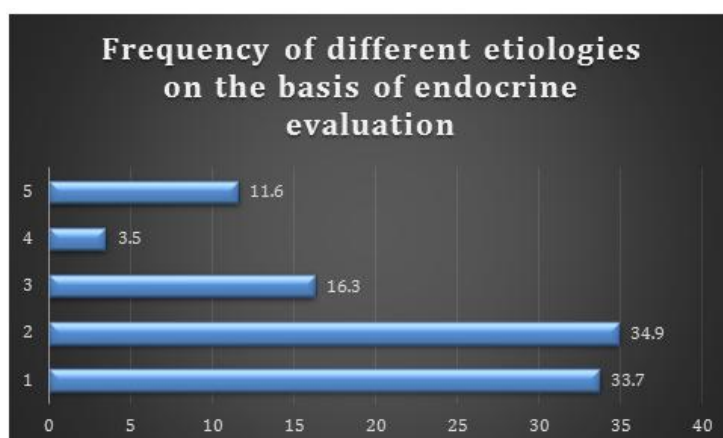


Fig-2: Different etiologies on the basis of endocrine evaluation. 1. Post testicular form 2. Primary testicular form (damage to spermatogenesis and Leydig cells) 3. Primary testicular form (damage to spermatogenesis) 4. Pre testicular form 5.Unspecified

Of the primary testicular form with damage to both spermatogenesis and Leydig cell damage (group 2, n=30), testosterone was normal in 17/30 (56.66%) and testosterone was low in 13/30 (43.33%). Of the primary testicular form with damage to spermatogenesis (group 3, n=14), testosterone was normal in 9/14 (64.28%) and testosterone was low in 5/14 (35.71%). Of the total 57 cases of non-obstructive azoospermia, 30 (52.6%) had testosterone deficiency.

Scrotal ultrasound findings were available in 59 cases. The findings are summarized in Table 2. Of the 29 cases with post testicular form scrotal USG was available in 17 cases. Of the 30 cases of primary testicular form with both spermatogenesis and Leydig's cell damage, scrotal USG was available in 23. There were 3/23(13%) cases of varicocele, 2 of them additional to small testis and one additional to epididymal cyst. Scrotal USG was available in 8 cases

of primary testicular form with damage to spermatogenesis. Pretesticular forms reported mild varicocele in one case. The unspecified variety with low

testosterone and normal FSH, LH had scrotal USG finding available in 9 cases.

Table-2: Scrotal sonogram findings in relation to endocrine diagnosis

Endocrine diagnosis/Scrotal USG findings	Normal findings	Testes abnormalities	Varicocele	Epididymal cyst
Post testicular n=17	12/17 (70.6%)	1/17 (5.9%)	5/17 (29.4%)	5/17 (29.4%)
Primary testicular (impaired spermatogenesis and Leydig cell function) n=23	6/23 (26.1%)	17/23 (73.9%) Bilateral Small testes 9/23 (39.1%) Unilateral small testis 2/23 (8.7%) Undescended testes 2/23 (8.7%)	3/23 (13.4%)	1/23 (4.3%)
Primary testicular (impaired spermatogenesis) n=8	3/8 (37.5%)	3/8 (37.5%)	1/8 (12.5%)	1/8 (12.5%)
Pre testicular n=2			1/2(50%)	
Unspecified n=9	5/9 (55.5%)	2/9 (22.2%) Testicular microlithiasis 1/9 (11.1%) Small testis (11.1%)	3/9 (33.3%)	3/9 (33.3%)
Total n=59	26/59 (44.1%)	23/59 (39%)	13/59 (22%)	10/59 (16.9%)

DISCUSSION

The objective of this retrospective study was to interpret the causes of severe male factor infertility by endocrine evaluation and scrotal ultrasound, so that appropriate counselling regarding treatment and prognosis can be done.

The thresholds used in this study were 300 ng/mL or 1040.15 mmol/L for testosterone, upper limit 7.6 IU/L, lower limit 1.2 IU/L for FSH/ LH [1, 7]. The threshold of FSH may be higher for Asian males [8]. The thresholds used in a study of Indian infertile males were 1.7-12 mIU/mL for FSH, 0.5-10 mIU/mL for LH, 3-12 ng/mL for testosterone [9].

About 34.9% of our infertile males with severe male factor had testosterone deficiency. Testosterone deficiency results in sexual dysfunction, visceral adiposity, osteoporosis, depression and lethargy, increased risk of metabolic syndrome, type 2 diabetes and cardiovascular disease [10]. Testosterone replacement therapy adversely affects fertility by causing hypogonadotropic hypogonadism. Severe male factor needs in vitro fertilization (IVF) with intracytoplasmic sperm injection (ICSI). The treatment has poor prognosis if associated with non-obstructive azoospermia. If the patient decides not to proceed for this treatment then we can offer him testosterone

replacement therapy as therapeutic and preventive measure.

Post testicular forms or obstructive azoospermia were suggested on the basis of normal testosterone, normal FSH and normal LH. Men with normal FSH and normal LH can have either non obstructive azoospermia or obstructive azoospermia [12]. So findings other than hormonal evaluation should be sought to search for obstruction in seminal tract. Clinical examination for the vas deferens, low semen volume (<1.5ml or <2 ml), pH <7.2, therapeutic trial to induce ante-grade ejaculation with pseudoephedrine or imipramine and to exclude retrograde ejaculation, presence of sperm in post-ejaculatory urine, absent or low seminal fructose (<13 micro mole/ejaculate), trans rectal ultrasound reporting ejaculatory duct cyst or dilated seminal vesicles suggest post testicular causes [11, 12]. The definitive diagnosis is not possible without testicular biopsy [4, 12]. Azospermia with normal histology of testes establishes the diagnosis of obstruction. Post-testicular causes have options other than IVF-ICSI such as surgical treatment in less than half of the cases. Vaso-vasostomy, vaso-epididymostomy, transurethral resection of ejaculatory duct, procedures dependent on expertise and experience of surgeons, may be available in selected centers [12].

Hormone analysis has important functions in evaluation and management of non-obstructive azoospermia. Non obstructive azoospermia includes pretesticular and testicular forms characterized by low or elevated FSH and LH. The group with low testosterone and normal FSH and LH could not be specified as primary testicular forms with either spermatogenesis and Leydig cell damage or Leydig cell damage only. The group had men with hypogonadism characterized by low testosterone. Normal or elevated LH and FSH levels with low testosterone characterize primary hypogonadism [4]. So normal FSH alone does not exclude impaired spermatogenesis. Abnormal spermatogenesis is reliably indicated by clear elevation of FSH or FSH level higher than twice the upper limit. Simple elevation of FSH does not unequivocally exclude obstruction or return to fertility [4].

The men with low FSH are identified to have hypogonadotropic hypogonadism with inadequate stimulation of testes by gonadotrophins. The incidence in our study was 3.5%, more than the 1-2% described for infertile men [15] as our population was only males with severe male factor. Medical therapy for non-obstructive azoospermia associated with hypogonadotropic hypogonadism (HH) include pulsatile GnRH therapy or gonadotropins and probably clomiphene citrate. At least 6 months of treatment aiming at increased testicular volume and normalization of hormones is preferable before sperm retrieval [10].

Men with non-obstructive azoospermia should have routine genetic testing and counselling for abnormal karyotype (eg XXY in Klinefelter Syndrome) and Y chromosome microdeletion prior to IVF-ICSI. More than 15% have their genetic diagnosis [3]. The prognosis of IVF-ICSI and the choice of having IVF – ICSI depend on it [13]. The spermatozoa to be used in IVF-ICS can be retrieved in about 34-44% of men with Klinefelter Syndrome through testicular sperm extraction (TESE). Carriers of complete AZFa and AZFb deletions have no chance of sperm retrieval from their testes by TESE [14]. The presence of a full AZFa and /or AZFb microdeletion is a contraindication of testicular biopsy for sperm extraction [3].

IVF –ICSI needs sperm retrieval. A diagnostic testicular biopsy may preclude more extensive procedures for sperm retrieval but for some men necessitates a second procedure for sperm retrieval. Sperm retrieval rate varies depending on biopsy results: 79-98% in hypo spermatogenesis, 47-98% in maturation arrest and 5-24% in Sertoli cell -only syndrome [15]. Testicular biopsy should only be performed in centers with the expertise of microsurgery and capacity of sperm cryopreservation. It should be offered to those men with azoospermia who agrees to sperm aspiration plus ICSI or vaso epididymostomy. Sperm retrieval modalities for obstructive azoospermia include percutaneous epididymal aspiration, open fine

needle aspiration, or open microsurgical epididymal aspiration. Sperm extraction is successful in 95% cases. But not all males with non-obstructive azoospermia have sperm in their testes and there are tubules without spermatogenesis intervening with tubules with complete spermatogenesis. Microdissection testicular sperm extraction (micro TESE) in several areas of testes has the best chance for sperm retrieval with lower postoperative complications. The sperm retrieval rate is 40-50% [12]. The biopsy sample is crushed and shredded with microscopic glass slides, the debris centrifuged and examined under high power microscope to explore spermatozoa. The live spermatozoa are collected and pooled by large needle or biopsy pipette in a clean drop of medium [5]. Micro-TESE is the standard procedure for sperm retrieval in men with non-obstructive azoospermia. With an operating microscope, larger seminiferous tubules can be identified and selectively extracted with higher chance of getting spermatozoa. There is less risk of injury to sub-tunical blood vessels, scarring and damage to testicular tissue. However the procedure is more costly and in need of expertise, not available in all centers [16]. Sperm vitrification device is now available to cryopreserve the single/few number of spermatozoa available [17].

Testicular biopsy has around 40-50% chance of sperm retrieval in men with non-obstructive azoospermia. Unsuccessful attempts lead to substantial emotional and financial consequences. There are some potential adverse effects like loss of vascularization and fibrosis [4]. Regarding health related disorders, cancer risk is three fold increased in men with non-obstructive azoospermia. Testosterone deficiency is prevalent (29-32%) in men with non-obstructive azoospermia and more after sperm retrieval procedures [10]. The proportion is 52.6% in our study probably because our men included those who already had testicular biopsy contributing to reduced function of testes.

Cetinkaya et al. did a retrospective study on 191 cases that had micro-TESE to assess the factors predicting success of sperm retrieval. The best cut off levels for differentiating successful and unsuccessful sperm retrieval was 15 mIU/mL for FSH (sensitivity 75%, specificity 51.2%, $p=.001$), 7.5 mIU/ mL for LH (sensitivity 63.1%, specificity 63.9%, $p=.001$) and 400 ng/ dl for total testosterone (sensitivity 52.2%, specificity 60%, $p=.023$) [18]. The cut off value of serum FSH was 4.09 IU/U with 90% sensitivity and 19% specificity for predicting positive outcome of TESE (positive predictive value 60%) [19]. These values indicate that serum FSH is not that reliable marker for prediction of successful sperm retrieval.

The scrotal ultrasound findings included small or absent testes, varicocele, epididymal cyst, testicular microlithiasis etc. Testicular volume measured by trans-scrotal ultrasound is correlated to testicular function. Doppler ultrasound may allow differentiation of

obstructive and non-obstructive azoospermia by normal or reduced blood flow [4]. The probability of sperm retrieval is poor when serum FSH is elevated or testes volume is low. A retrospective study of 51 Chinese males with obstructive azoospermia and 156 Chinese males with non-obstructive azoospermia, diagnosed by testicular biopsy, revealed that a combination of FSH >9.2 mIU/ml and right testis size <15 ml, can predict non-obstructive azoospermia with positive predictive value 99.2% [8]. The cut off value of 7.6 mIU/ml and a testicular long axis of 4.6 cm was decided by the study on Caucasian males [7].

Azoospermia results in 30% and 80% cases from untreated unilateral and bilateral undescended testes respectively. Cryptorchidism is likely to cause azoospermia by testicular dysgenesis, impaired endocrine axis, immunologic damage or obstruction. Early treatment before the child's first birthday minimizes risk of infertility [2].

Varicoceles are abnormal venous dilatations of the pampiniform plexus [6]. Varicocele progressively damage testicular function. The prevalence of azoospermia associated with varicocele is 5-10%. Again, 75% of men with varicocele have normal semen parameters [2]. Varicocele is found in 4.3-13.3% of men with severe male factor [15]. In our study it was 22% probably because it included those found not clinically but on sonogram. Following varicocele repair by ligation or embolization in men with non-obstructive azoospermia, ejaculated sperm is detected in 44%. Testicular biopsy with semen cryopreservation is recommended at the same time of varicocele repair. Benefit is more apparent when histology is hypo spermatogenesis than maturation arrest or Sertoli cell - only syndrome, a fact important for counselling. Azoospermia may relapse at varying intervals following varicocele repair. Reported pregnancy rate following varicocele repair is 6%-13.6% when spontaneous and 4%-18.9% via assisted reproductive techniques with ejaculated sperm. Varicocele may improve sperm retrieval rate for ICSI, the recommended interval being 3 months [15].

Epididymal cyst may be the result of trauma or inflammation of epididymis leading to obstruction of proximal genital tract [6]. Epididymal cysts were present not only in post testicular form but also in primary testicular forms of our participants which may be explained by mixed pathogenesis eg infections and inflammation affecting both testes and epididymis.

Testicular microlithiasis means multiple calcifications in testicular parenchyma [6]. Testicular microlithiasis, in addition to male infertility, is associated with higher risk for testicular cancer. Testicular microlithiasis ≥ 5 per scrotal sonogram may be associated with more severe testicular dysfunction in infertile men [20].

The findings of our study indicate that scrotal ultrasound findings do not agree with endocrine diagnosis in all cases. The findings like testes abnormalities or varicocele were present in those grouped as obstructive cause. This is in favor of the report that men with normal FSH and normal LH can have either non obstructive azoospermia or obstructive azoospermia [12]. Findings like epididymal cyst were present in non-obstructive azoospermia or severe oligospermia. The explanation may be that mixed forms were present or that sonographic findings do not have clear association with endocrine diagnosis.

Endocrine evaluation largely allows specific diagnosis and management strategies in severe male factor. Endocrine screening should begin with serum testosterone and FSH to detect many endocrinopathies. If testosterone level is low, further analysis of total and free testosterone, LH, prolactin and estradiol may help explain the etiology [2]. Endocrine assessment should be interpreted on the context of the patient's history, testicular volumes and associated co- morbidities [1].

FSH is required for initiation of spermatogenesis, but it alone cannot be used as a marker of spermatogenesis or predictor of sperm retrieval. Normal or elevated FSH is associated with both normal and impaired spermatogenesis. FSH values higher than twice the normal indicate germinal epithelial destruction. Normal or elevated FSH is seen with different testicular histologies such as hypo spermatogenesis or Sertoli cell-only syndrome. Testosterone is important for spermatogenesis. But men with severe male factor can have normal to lower normal values of testosterone [9].

Despite all limitations, serum total testosterone and follicle-stimulating hormone (FSH) estimation is necessary for evaluation of azoospermia and severe oligospermia. Men with non- obstructive azoospermia should be counselled about different aspects like appropriate therapeutic alternatives to immediate sperm retrieval, advantages and disadvantages of available sperm retrieval procedures and protocols and treatment of underlying relevant health conditions. For example men with Klinefelter syndrome are at risk for testosterone deficiency, osteoporosis, metabolic syndrome, type 2 diabetes, breast cancer and extra gonadal germ cell tumors. Genetic testing is offered because if positive there is chance of genetic defect in offspring conceived by assisted reproductive technologies [15]. There are few evidences of hormonal optimization therapy in men with primary testicular failure. Treatment with aromatase inhibitor letrozole in men with non- obstructive azoospermia have led to sperm in ejaculation [12]. Hormonal evaluation however predict the success of medical therapy and surgical sperm retrieval [12].

The limitations of the study are its retrospective nature. However the study defined the strategies of handling these patients with severe male factor from low socio economic background for whom IVF-ICSI is not the best management option.

CONCLUSION AND RECOMMENDATION

Majority of men with severe male factor infertility has non-obstructive azoospermia which has poor chance of sperm retrieval for IVF-ICSI. Substantial proportion of them has testosterone deficiency. Since IVF-ICSI itself and IVF-ICSI with donor sperm is not acceptable to our patients, management strategies should focus on counselling, adoption or childless living and possible testosterone replacement.

ACKNOWLEDGEMENT

We express our gratitude to the FCPS subspecialty trainees in Reproductive Endocrinology & Infertility who worked in Male infertility clinic, the men who have been part of the study and the allied departments providing the investigation facilities.

REFERENCES

1. Ferlin, A., Foresta, C. (2020). Infertility: Practical clinical issues for routine investigations of the male partner, 4,1644 www.mdpi.com/journal/jcm
2. Cocuzza, M., Alvarenga, C., Pagani, R. (2013). The epidemiology and etiology of azoospermia. *Clinics*, 68(51), 15-26
3. Ghieh, F., Mitchell, V., Mandon-Pepin, B., Vialard, F. (2019). Genetic defects in human azoospermia. *Basic and Clinical Andrology*, 29(4)
4. Gudeloglu, A., Parekatil, S.A. (2013). Update in evaluation of the azoospermic male. *Clinics*, 68(5):27-34
5. Ghanem, M., Bakr, N.I., Elgyaar, M.A., El Mongy, S., Fathy, S., Ibrahim, A.H.A. (2005). Comparison of the outcome of intracytoplasmic sperm injection in obstructive and non-obstructive azoospermia in first cycles: a report of case series and meta-analysis. *Int J Androl*, 28, 16-21
6. Ugboma, E.W., Manuel, B.A. (2021). Pathological scrotal findings in infertile men at a tertiary hospital in south South Nigeria. *Asian J Res Rep Urol*, 4(2), 8-18
7. Schoor, R.A., Elhanbly, S., Niederberger, C.S., Ross, L.S. (2002). The role of testicular biopsy in modern management of male infertility. *J Urol*, 167,197-200
8. Huang, I.S., Huang, W.J., Lin, A.T. (2018). Distinguishing non- obstructive azoospermia from obstructive azoospermia in Taiwanese patients by hormone profile and testes size. *J Chinese Med Assoc*, 81, 531-535
9. Abid, S., Maitra, A., Meherji, P., Patel, Z., Kadam, S., Shah, J. (2008) Clinical and laboratory evaluation of idiopathic male infertility in a secondary referral center in India. *J Clin Lab Analysis*, 22, 29-38
10. Kumar, R. (2013). Medical management of non-obstructive azoospermia. *Clinics*, 68(51), 75-79
11. Kim, D.K., Lee, H.H., Yoon, Y.E., Park, S.Y., Lee, S.R., Hong, Y.K. (2018). Does imipramine and pseudoephedrine medical treatment have clinical implication in treatment of retrograde ejaculation caused by diabetes mellitus? *J Urol*,199(4S), e1170, MP85-04
12. Jarvi, K., Lo, K., Grober, E., Mak, V., Fischer, A., Grantmyre, J. (2010). CUA Guideline: The workup and management of azoospermic males. *Can Urol Assoc J*, 4(3), 163-7
13. Alhalabi, M., Kenj, M., Monem, F., Mahayri, Z., Alchamat, G.A., Madania, A. (2013). High prevalence of genetic abnormalities in Middle Eastern patients with idiopathic non obstructive azoospermia. *J Assist Reprod Genet*, 30,799-805
14. Cioppi, F., Rosta, V., Krausz, C. (2021). Genetics of azoospermia. *Int J Mol Sci*, 22, 3264 <https://doi.org/10.3390/ijms22063264>
15. The Practice Committee of the American Society for Reproductive Medicine. (2018). Management of non-obstructive azoospermia: a Committee opinion. *Fertil Steril*, 110(7), 1239-1245
16. Franco, G., Scarcelli, F., Casciani, V., Nunzio, C.D., Dente, D., Leonardo, C. (2016). A novel stepwise micro- TESE approach in non-obstructive azoospermia. *BMC Urology*,16, 20
17. Pai, H., Handa, M., Kaur, A., Palshetkar, N., Pai, R., Palshetkar, R. (2021). Azoospermia-Novel management in current era. *Bangladesh J Fertil Steril*, 1(1), 36-46
18. Cetinkaya, M., Onem, K., Zorha, O.U., Ozkara, H., Alici, B. (2015). Evaluation of microdissection testicular sperm extraction results in patients with non- obstructive azoospermia: independent predictive factors and best cut off values for sperm retrieval. *Sexual Dysfunction and Infertility*, 12(6),2015,2436-2443
19. Tunc, L., Kirac, M., Gurocak, S., Yucel, A., Kupeli, B., Alkibey, T. (2006). Can serum inhibin B and FSH levels, testicular histology and volume predict the outcome of testicular sperm extraction in patients with non-obstructive azoospermia? *Int J Urol Nephrol*, 38, 629-635
20. Andrea, S.D., Martorella, A., Castellini, C., Cordeschi, G., Totaro, M., Parisi, A. (2021). Clinical and seminal parameters associated with testicular microlithiasis and its severity in males from infertile couples. *Hum Reprod*, 36(4),891:898