

Appendicitis in Pregnant Women, Place of laparoscopy: Retrospective Study of 15 Cases

Elloumi Habib*, Ben Slima M, Lassoued I

Department of General Surgery B, Rabta Hospital, Tunis, Tunisia

DOI:10.21276/sb.2019.5.7.7

| Received: 12.07.2019 | Accepted: 22.07.2019 | Published: 30.07.2019

*Corresponding author: Elloumi Habib

Abstract

Introduction: Acute appendicitis is the surgical emergency that occurs most often in pregnant women with a prevalence of 0.05 to 0.1%. It is a clinical entity that gives in to diagnostic problems. The treatment of appendicitis in pregnant women is surgical. The use of the laparoscopic route depends mainly on the age of pregnancy, the location of the appendix and the presence of complications. The prognosis is maternal and fetal and the mortality varies from 0.5 to 1.5%. **Material and Methods:** This is a retrospective study of 15 cases treated in the general surgery department B of the Rabta hospital from 2011 to 2018. **Results:** This is a series of 15 patients whose average age was 27 years with extremes of 20 and 39 years. Among our patients, 2 had a caesarean section median, 2 had a right subcostal for cholecystectomy, and one patient had a umbilical hernia plate replacement. The age of pregnancy was in the 2nd trimester in 8 patients. The duration of evolution of the symptomatology was on average 2 days. Pain in the right iliac fossa was present in 8 patients. A fever was observed in 2 patients. Vomiting was noted in 6 patients. A biological inflammatory syndrome was present in 7 patients. Abdominal ultrasonography, performed in 10 patients, made it possible to retain the diagnosis in 6 patients. Tocolysis was performed in all cases. The appendectomy was performed laparoscopically in 9 patients. Seven of them had a term less than 20 SA. The least advanced pregnancy was 8 SA and the most advanced 24 SA. The Mac Burney pathway was performed in 5 patients and one patient was operated on by median laparotomy. The appendix was inflammatory in 2 patients, phlegmonous in 5 patients, gangrenous in 4 patients and perforated in 4 patients including an appendiceal abscess in 3 cases and peritonitis in one case. Drainage was performed in 4 patients. The postoperative courses were marked by a wall abscess in 3 patients, Premature delivery for one and a spontaneous abortion for one. **Conclusion:** Acute appendicitis in pregnant women is a diagnostic problem mainly in the 2nd and 3rd trimesters of pregnancy. The laparoscopic approach has been described at any age of pregnancy, but it is far from being considered a gold standard for appendicitis in pregnant women; studies are underway to assess the long-term course of children whose mothers have had laparoscopic appendectomy.

Keywords: laparoscopically, Appendicitis in Pregnant, phlegmonous, appendiceal.

Copyright © 2019: This is an open-access article distributed under the terms of the Creative Commons Attribution license which permits unrestricted use, distribution, and reproduction in any medium for non-commercial use (NonCommercial, or CC-BY-NC) provided the original author and source are credited.

INTRODUCTION

Acute appendicitis is the surgical emergency that occurs most in pregnant women with a prevalence of 0.05 to 0.1% [1-3]. Most series report women between the ages of 20 and 30 [4]. The clinic in some cases gives in to a doubt diagnosis [1], the abdominal ultrasound remains the examination of 1st intension with a sensitivity and specificity to 96 and 100% [5]. The surgical treatment remains the gold standard [6]. The mortality is 1 to 8% and can reach 35% in case of perforation [7, 8].

OBJECTIVES

The objective of this study is to report the peculiarities of our series and to evaluate our support.

MATERIALS AND METHODS

This is a retrospective study of 15 appendicitis cases followed at our general surgery department at La Rabta hospital from 2011 to 2019. Epidemiological data include maternal and gestational age, duration of evolution of symptomatology, clinical data, para-clinical, pathological and follow-up postoperative maternofetal were reviewed.

RESULTS

This is a series of 15 patients whose average age was 27 years with extremes of 20 and 39 years. Among our patients, 2 had a caesarean section median, 2 had a right subcostal for cholecystectomy, and one

patient had a umbilical hernia plate replacement. The age of pregnancy was in the 2nd trimester in 8 patients. The duration of evolution of the symptomatology was on average 2 days. Pain in the right iliac fossa was present in 8 patients. A fever was observed in 2 patients. Vomiting was noted in 6 patients. A biological inflammatory syndrome was present in 7 patients.

Abdominal ultrasonography, performed in 10 patients, made it possible to retain the diagnosis in 6 patients. Tocolysis was performed in all cases. The appendectomy was performed laparoscopically in 9 patients. Seven of them had a term less than 20 SA. The least advanced pregnancy was 8 SA and the most advanced 24 SA (Table-1).

Table-1: Clinical symptomatology, biological and radiological data

NO	Age	Terme (SA)	Durée d'évolution (H)	Site of pain	Uterine contracture	Temperature °C	Vomiting	CRP	Abdominal and pelvic echography
1	20	15	72	FID	+	37.9	+	30	appendicitis
2	30	16	48	FID	+	37.2	—	50	appendicitis
3	28	24	24	HCD	—	37.8	—	40	appendicitis
4	29	18	72	HCD	—	37.8	—	50	—
5	30	17	48	FID	—	37.7	—	20	Appendicitis not seen
6	29	14	48	FID	—	37.8	—	40	appendicitis
7	39	33	72	widespread	+	38.5	—	150	—
8	23	20	48	HCD	+	37.7	—	15	appendicitis
9	22	21	48	HCD	+	37.7	—	25	Appendicitis not seen
10	21	7	72	FID	—	38.2	+	60	appendiceal abscess
11	25	9	24	HCD	—	37.8	—	10	Appendicitis not seen

No complicated appendicitis was operated laparoscopically. No conversions have been made. The Mac Burney pathway was performed in 5 patients and one patient was operated on by median laparotomy. The appendix was inflammatory in 2 patients, phlegmonous in 5 patients, gangrenous in 4 patients and perforated in

4 patients including an appendiceal abscess in 3 cases and peritonitis in one case. Drainage was performed in 4 patients. The postoperative courses were marked by a wall abscess in 3 patients, Premature delivery for one and a spontaneous abortion for one (Table-2).

Table-2: Surgical approach and preoperative findings

NO	Terme (SA)	laparoscopy (9)	Way of Mac Burney (5)	Median Laparotomy	Preoperative finding	Operative suites Maternal-fetal
1	15	—	+	—	phlegmonous appendage	—
2	16	—	+	—	appendiceal abscess	abscess wall
3	24	+	—	—	phlegmonous appendage	—
4	18	+	—	—	appendiceal abscess	—
5	17	+	—	—	inflammatory appendage	—
6	14	—	+	+	phlegmonous appendage	—
7	33	—	—	—	appendiceal peritonitis	premature delivery
8	20	—	+	—	phlegmonous appendage	abscessed wall
9	21	+	—	—	inflammatory appendage	—
10	7	—	+	—	appendiceal abscess	abscessed wall
11	9	+	—	—	phlegmonous appendage	—
12	16	+	—	—	gangrenous appendage	—
13	8	+	—	—	gangrenous appendage	—
14	6	+	—	—	gangrenous appendage	Spontaneous abortion
15	10	+	—	—	gangrenous appendage	—

DISCUSSION

The age of the patients varies in our series of 20 to 40 years, the series evoke a range of age from 20 to 30 years; this difference would be related to the age of marriage, which is more and more late, and to the local socio-economic context [1, 5]. The occurrence of appendicitis in pregnancy varies in age from one author to another [9, 10], multiple authors report that appendicitis occurs mostly in the 2nd trimester, which consistent with our results [12-15]. But according to Gomez and wood, appendicitis can occur at any time during pregnancy [11]. The symptomatology in our

series is often similar to that of classical appendicitis in the first trimester (Table-1); similar to the literature with pain in the right iliac fossa frequently found [17], the diagnosis was difficult in the 2nd and 3rd semester by the presence of pain in the right hypochondrium, uterine contractions, vomiting and nausea; this is explained by the repression of the appendix above and beyond all the more that the semiology of appendicitis can be associated with physiological symptoms of pregnancy [2, 16-18]. Four cases of complicated appendicitis were found in our series, 3 of which occurred in the 2nd and 3rd trimesters (Table-2);

complicated forms in pregnant women occur in the last 2 trimesters, appendiceal perforation is more frequent in the 3rd trimester; due to increased levels of steroid hormones which reduce the inflammatory response, uterine contractions that reduce the confinement of infection and increased pelvic vascularization facilitating the spread of infection [1, 22, 37]. In our series leukocytosis and high CRP were marked in 7 cases (Table-1); biology remains a guiding element for the diagnosis especially as the blood count is difficult to interpret because of leukocytosis physiologic in pregnant women and CRP which may be normal [7]. In case of doubt diagnosis, the abdominal ultrasound allows retaining the positive diagnosis when it shows direct or indirect signs of appendicitis (Fig 1 & 2).

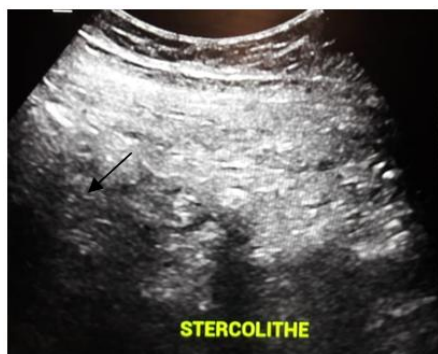

Fig-1: Stercolith

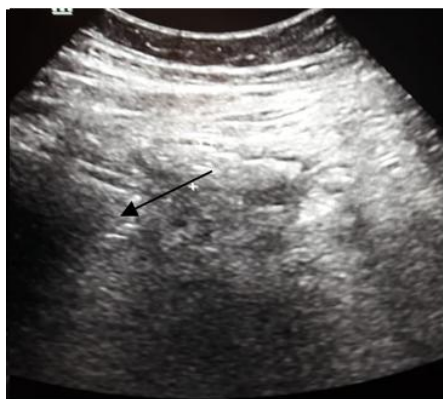

Fig-2: Tumbled appendix at 13 mm with infiltration

She also finds an interest in the demonstration of adnexal or obstetric pathology [7]. It is the 1st choice examination, confirms the diagnosis with a sensitivity of 96 to 100% and a specificity of 92% to 96% [5, 19], this examination remains dependent operator and can be embarrassed in the last two months of pregnancy by uterine repression on the appendix, which would explain the 4 cases of appendicitis not seen in our series (Table-1) [22]. Coeliagnosis has been performed in our series 4 times (Table-2); in cases where the diagnosis was doubtful and the ultrasonography was not fruitful, from where its interest in the positive and differential diagnosis and thus making it possible to avoid white laparotomy [2, 27]. An abdominal CT showing appendicitis peritonitis was performed in one patient after delivery at her 33 WA (Table-1); some authors

recommend abdominal CT in the 3rd trimester of pregnancy [19, 20]. It is recommended to perform an abdominal MRI for the diagnosis of appendicitis in a pregnant woman, this examination eliminates the diagnosis; no MRI in our series has been performed because of the inaccessibility in emergency cases of this examination [23]. Surgical appendectomy, currently, is the reference treatment for appendicitis in pregnant women [25]. In our series, the treatment was done surgically under an antibiotic cover, the approach was discussed according to the age of the pregnancy, the surgical antecedents and the gravity of the affection; 5 Mac Burney appendectomies were performed for patients with a scarred abdomen for first and second trimester pregnancies, two of which were complicated with abscess, 9 laparoscopic appendectomies were performed for pregnancies ranging from 6th week of amenorrhea to the 24th and one patient at her 33rd amenorrhea was operated median for appendicular peritonitis resulting a premature delivery and severe sepsis (Table-2). A meat-analysis comparing the efficacy of antibiotic versus surgical treatment for uncomplicated appendicitis concludes that antibiotic therapy can be used as first-line treatment for simple appendicitis at the risk of recurrence in 30% of cases [26]. The consensus conference to develop guidelines for laparoscopic appendectomy concludes that there is no consensus regarding appendicitis in pregnant women, it is considered safe for mother and fetus in the 1st and 2nd trimester, recommendation grade IIb is not sufficient to judge laparoscopy as gold standard for appendicitis in pregnant women [44]. Laparoscopy is contraindicated for some authors starting from the 20th week of amenorrhea due to increased risk of uterine wound and maternal-fetal risk due to increased intra-abdominal pressure and pneumoperitoneum reducing flow rate. However, some authors consider that it is possible to have a laparoscopic approach at 20th week of amenorrhea and even beyond, exploiting the space between the xiphoid appendix and the uterine fundus; this has been the case for our series [28, 29]. Nezhat *et al.*, work in 93 pregnant patients with laparoscopic appendectomies in pregnant women has demonstrated the feasibility of safe appendectomy, but the laparoscopic approach is prone to utero-visceral lesions and acid-base disorders for the fetus. Essentially, in the 3rd quarter [35]. A meta-analysis by Jackson *et al.* demonstrated the feasibility of appendisectomy at any time of pregnancy by laparoscopy with better maternal-fetal results compared to laparotomy in terms of duration of hospitalization, postoperative pain, wound abscess, thromboembolic complications and fetal loss [36] [38]. One study followed the course of 11 children whose mothers had a laparoscopic appendectomy from the age of 1 to 8 years, no psychomotor developmental disorder or growth were noted [39]. The American society of gastroenterology and endoscopic surgery as well as several studies recommends during the pregnancy an open technique with Hasson, a pressure of 10 to 12 mmHg with a time of operation of 60 min in

order to avoid the complications relative to laparoscopy [36, 38, 40]. The trocars are placed according to the preferences of the surgeon, but always with a cephalic translation of these with a position in the left lateral decubitus of the patient or a rotation to the left of the operating table thus avoiding compression of the inferior vena cava and making the appendix more accessible [37]. In our study we did preventive tocolysis to all our patients (Table-2); Lebeau recommends perioperative preventive tocolysis to avoid the risk of premature labor and spontaneous abortion; however, a recent study has shown that there is no significant difference in outcome between the tocolysis and non-tocolysis group, so tocolysis should only be performed in case of obstetric indications [24, 41]. Fetal monitoring is recommended before and after the procedure (Fig-3) [42].

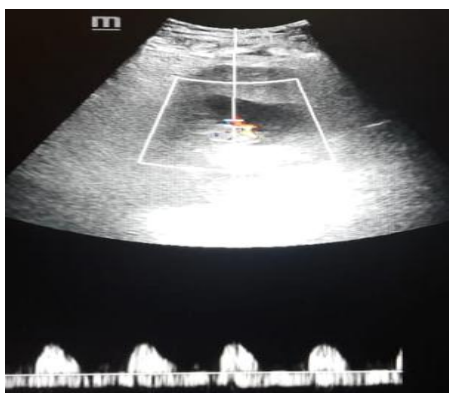


Fig-3: Ultrasonographie view of positive fetal activity in a patient at her 7th week of amenorrhea

The maternal-fetal prognosis is a function of the therapeutic delay and the severity of the condition, the fetal mortality amounts to more than 35% in case of appendicular peritonitis and varies from 1 to 8% for the pregnant woman [7, 30-32]. The fetal risks described in the literature are mainly prematurity and spontaneous abortion; cases of intrauterine fetal death and intrauterine growth retardation have been noted; these complications are all the greater as the age of pregnancy is advanced and the appendix is perforated [27, 33, 34]. In our case, premature delivery was observed in a patient with peritonitis and spontaneous abortion occurred in a laparoscopic appendectomy patient at her 6th week of amenorrhea (Table-2). The postoperative complications for the mother are mainly wound abscess with an incidence of 8 to 15% occurring during complicated appendicitis and are more frequent in laparotomy [18, 24], they are prevented by a broad-spectrum antibiotic [43]; in our series, 3 wound abscesses were observed, all for Mc Burney appendectomy, of which 2 were appendicular abscess (Table-2). Postoperative ileus, respiratory complications and intra-abdominal abscess are also mentioned, we did not get these complications in our study (Table-2) [4].

CONCLUSION

Acute appendicitis in pregnant women poses a diagnostic problem mainly in the 2nd and 3rd trimesters of pregnancy. Abdominal ultrasound is the first choice exam to support the diagnosis, but it keeps its limits. Some authors recommend abdominal CT in the 3rd trimester and MRI for positive diagnosis. The laparoscopic approach has been described at any age of pregnancy, but it is far from being considered a gold standard for appendicitis in pregnant women; studies are underway to assess the long-term course of children whose mothers have had laparoscopic appendectomy.

REFERENCES

1. Leroy, J. L. (1981). L'appendicite aiguë au cours de la gravidité-puerpéralité: les difficultés du diagnostic et du traitement. *Med Chir Dig*, 10, 143-147.
2. Marret, H., Laffon, M., De Calan, L., Bourlier, L. P., & Lansac, J. (2000). Urgences chirurgicales au cours de la grossesse. *Encycl Méd Chir (éditions Scientifiques et Médicales Elsevier SAS, Paris, Gynécologie-Obstétrique, 5-049-D-10, 2000, 13p.*
3. Chambon, J. P., Quandalle, P., Regnier, C., Delecour, M., & Ribet, M. (1986). Les urgences abdominales non gynécologiques durant la grossesse. In *Annales de chirurgie*, 40(7), 455-461. Elsevier.
4. Jung, S. J., Do Kyung Lee, J. H. K., Kong, P. S., Kim, K. H., & Bae, S. W. (2012). Appendicitis during pregnancy: the clinical experience of a secondary hospital. *Journal of the Korean Society of Coloproctology*, 28(3), 152.
5. Lim, H. K., Bae, S. H., & Seo, G. S. (1992). Diagnosis of acute appendicitis in pregnant women: value of sonography. *AJR. American journal of roentgenology*, 159(3), 539-542.
6. El Ghali, M. A., Kaabia, O., Mefteh, Z. B., Jgham, M., Tej, A., Sghayer, A., ... & Letaief, R. (2018). Acute appendicitis complicating pregnancy: a 33 case series, diagnosis and management, features, maternal and neonatal outcomes. *The Pan African Medical Journal*, 30.
7. Dufour, P., Delebecq, T., Vinatier, D., Haentjens-Verbeke, K., Tordjeman, N., Prolongeau, J. F., ... & Puech, F. (1996). Appendicite et grossesse: A propos de 7 observations. *Journal de gynécologie obstétrique et biologie de la reproduction*, 25(4), 411-415.
8. Mahmoodian, S. (1992). Appendicitis complicating pregnancy. South 5. Touhami H. Appendicite et grossesse: les conditions du suc. *Med J*, 85: 19-22.
9. Andersson, R. E., & Lambe, M. (2001). Incidence of appendicitis during pregnancy. *International journal of epidemiology*, 30(6), 1281-1285.
10. Neto, F., Amorim, M. M. R. D., & Nóbrega, B. M. S. V. (2015). Acute appendicitis in pregnancy: literature review. *Revista da Associação Médica Brasileira*, 61(2), 170-177.

11. Gomez, A., & Wood, M. (1979). Acute appendicitis during pregnancy. *The American Journal of Surgery*, 137(2), 180-183.
12. Shin, T. S. (1970). Clinical observation appendectomy during pregnancy. *J Korean Surg Soc*, 12, 13-16.
13. Kim, L. S., Lee, Y. C., Kim, D. K., Kim, S., Choi, W. J., Lee, J. M., & Suk, H. (1993). A clinical study of acute appendicitis in pregnancy. *Journal of the Korean Surgical Society*, 44(6), 847-856.
14. Ahn, D. H. (1997). Acute appendicitis during pregnancy. *Journal of Korean Soc Coloproctol*, 13:509-516
15. Kim, D. H., Lee, I. K., Choi, S. B., Lee, Y. S., Lee, S. K., Oh, S. T., ... & Chang, S. K. (2008). Laparoscopic vs. Conventional Appendectomy in Pregnancy. *Journal of the Korean Society of Coloproctology*, 24(3), 161-165.
16. Lemine, M., Collet, M., & Brettes, J. P. (1994). Urgences abdominales et grossesse: Les urgences en gynécologie obstétrique. *Revue française de gynécologie et d'obstétrique*, 89(11), 553-559.
17. Mourad, J., Elliott, J. P., Erickson, L., & Lisboa, L. (2000). Appendicitis in pregnancy: new information that contradicts long-held clinical beliefs. *American journal of obstetrics and gynecology*, 182(5), 1027-1029.
18. Yilmaz, H. G., Akgun, Y., Bac, B., & Celik, Y. (2007). Acute appendicitis in pregnancy—risk factors associated with principal outcomes: a case control study. *International Journal of Surgery*, 5(3), 192-197.
19. Rosen, M. P., Ding, A., Blake, M. A., Baker, M. E., Cash, B. D., Fidler, J. L., ... & Lalani, T. (2011). ACR Appropriateness Criteria® right lower quadrant pain—suspected appendicitis. *Journal of the American College of Radiology*, 8(11), 749-755.
20. Freeland, M., King, E., Safcsak, K., & Durham, R. (2009). Diagnosis of appendicitis in pregnancy. *the American journal of surgery*, 198(6), 753-758.
21. van Randen, A., Bipat, S., Zwinderman, A. H., Ubbink, D. T., Stoker, J., & Boermeester, M. A. (2008). Acute appendicitis: meta-analysis of diagnostic performance of CT and graded compression US related to prevalence of disease. *Radiology*, 249(1), 97-106.
22. Maisonnète, F., Dubayle, G., Aubard, Y., & Baudet, J. H. (1999). Appendicite aiguë au cours des deux derniers trimestres de la grossesse. *Revue française de gynécologie et d'obstétrique*, 94(1), 66-69.
23. Pedrosa, I., Levine, D., Eyvazzadeh, A. D., Siewert, B., Ngo, L., & Rofsky, N. M. (2006). MR imaging evaluation of acute appendicitis in pregnancy. *Radiology*, 238(3), 891-899.
24. Lebeau, R., Diané, B., Koffi, E., Bohoussou, E., Kouamé, A., & Doumbia, Y. (2005). Appendicite aiguë et grossesse: à propos de 21 cas. *Journal de gynécologie obstétrique et biologie de la reproduction*, 34(6), 600-605.
25. El Ghali, M. A., Kaabia, O., Mefteh, Z. B., Jgham, M., Tej, A., Sghayer, A., ... & Letaief, R. (2018). Acute appendicitis complicating pregnancy: a 33 case series, diagnosis and management, features, maternal and neonatal outcomes. *The Pan African Medical Journal*, 30:212
26. Varadhan, K. K., Neal, K. R., & Lobo, D. N. (2012). Safety and efficacy of antibiotics compared with appendectomy for treatment of uncomplicated acute appendicitis: meta-analysis of randomised controlled trials. *Bmj*, 344, e2156.
27. Noura, M., Jerbi, M., Sahraoui, W., Mellouli, R., Sakhri, J., Bouguizane, S., ... & Khairi, H. (1999). Appendicite aiguë chez la femme enceinte: à propos de 18 cas. *Revue française de gynécologie et d'obstétrique*, 94(6), 486-491.
28. Batallan, A., Benifla, J. L., Panel, P., Dorin, S., Darai, E., & Madelenat, P. (1999). Chirurgie laparoscopique au deuxième trimestre de la grossesse: indications, technique et retentissement foetal: A propos de neuf observations et revue de la littérature. In *Annales de chirurgie*, 53(4), 285-290. Elsevier.
29. Barnes, S. L., Shane, M. D., Schoemann, M. B., Bernard, A. C., & Boulanger, B. R. (2004). Laparoscopic appendectomy after 30 weeks pregnancy: report of two cases and description of technique. *American Surgeon*, 70(8), 733-736.
30. Tshibagu-Kangu, K., Alardo, J. P., Lieselele - Bolemba, L., & Makanya, K. (1985). Risque materno-foetale de l'appendice et grossesse en afrique centrale. *Ann Sac belge Med Trop*. 65: 369-672.
31. Nabil, S., Ben said, F., & El Hajaoui, S. C. (1994). Peritonite et grossesse. *Maghreb Medicale*, 281:19-21.
32. Babakania, A., Parsa, H., & Woodruff, J.D. (1977). Appendisectomy during pregnancy. *Obstet Gynecol*, 5: 40-44.
33. Halvorsen, A. C., Brandt, B., & Andreassen, J. J. (1992). Acute appendicitis in pregnancy: complications and subsequent management. *The European journal of surgery= Acta chirurgica*, 158(11-12), 603-606.
34. Allen, J. R., Helling, T. S., & Langenfeld, M. (1989). Intraabdominal surgery during pregnancy. *The American journal of surgery*, 158(6), 567-569.
35. Nezhat, F. R., Tazuke, S., Nezhat, C. H., Seidman, D. S., Phillips, D. R., & Nezhat, C. R. (1997). Laparoscopy during pregnancy: a literature review. *JSLS: Journal of the Society of Laparoendoscopic Surgeons*, 1(1), 17-27.
36. Machado, N. O., & Grant, C. S. (2009). Laparoscopic appendectomy in all trimesters of pregnancy. *JSLS: Journal of the Society of Laparoendoscopic Surgeons*, 13(3), 384-390.

37. Weingold, A. B. (1983). Appendicitis in pregnancy. *Clinical obstetrics and gynecology*, 26(4), 801-809.
38. Jackson, H., Granger, S., Price, R., Rollins, M., Earle, D., Richardson, W., & Fanelli, R. (2008). Diagnosis and laparoscopic treatment of surgical diseases during pregnancy: an evidence-based review. *Surgical endoscopy*, 22(9), 1917-1927.
39. Rizzo, A. G. (2003). Laparoscopic surgery in pregnancy: long-term follow-up. *Journal of laparoendoscopic & advanced surgical techniques*, 13(1), 11-15.
40. Society of American Gastrointestinal Endoscopic Surgeons (SAGES). (1998). Guidelines for laparoscopic surgery during pregnancy. *Surg Endosc*.12:189-190.
41. Walsh, C. A., Tang, T., & Walsh, S. R. (2008). Laparoscopic versus open appendectomy in pregnancy: a systematic review. *International Journal of Surgery*, 6(4), 339-344.
42. Rollins, M. D., Chan, K. J., & Price, R. R. (2004). Laparoscopy for appendicitis and cholelithiasis during pregnancy: a new standard of care. *Surgical Endoscopy And Other Interventional Techniques*, 18(2), 237-241.
43. Sauerland, S., Jaschinski, T., & Neugebauer, E. A. (2010). Laparoscopic versus open surgery for suspected appendicitis. *Cochrane Database of Systematic Reviews*, (10).
44. Vettoretto, N., Gobbi, S., Corradi, A., Belli, F., Piccolo, D., Pernazza, G., ... & Italian Association of Hospital Surgeons (Associazione dei Chirurghi Ospedalieri Italiani). (2011). Consensus conference on laparoscopic appendectomy: development of guidelines. *Colorectal Disease*, 13(7), 748-754.